

# Inhomogeneity of Left Ventricular Apical Rotation during the Heart Cycle Assessed by Ultrasound Cardiography

N Bachner<sup>1</sup>, Z Friedman<sup>1</sup>, W Fehske<sup>2</sup>, D Adam<sup>1</sup>

<sup>1</sup>Department of Biomedical Engineering, Technion, Haifa, Israel

<sup>2</sup>Clinic for Internal Medicine and Cardiology, Vinzenz-hospital, Köln, Germany

## Abstract

*Efficient function of the left ventricle involves a wringing motion that facilitates ejection and filling. Previous studies reported that various pathologies, even at their early stages, affect the left ventricular global and local rotation. The present study was undertaken to develop myocardial rotation mapping technique of high spatial and temporal resolutions.*

*Rotation maps were derived by processing of apical short-axis cine-echocardiograms in 10 normal human subjects utilizing a novel ultrasound speckle tracking method and high resolution processing.*

*The results show heterogeneity among myocardial layers and at different locations, with larger rotations of the inner layers, and of the posterior wall versus the septum. Thus, echocardiographic mapping of LV rotation is feasible, allowing assessment of myocardial functional heterogeneity that may provide early indication of pathologies and remodeling.*

## 1. Introduction

The left ventricle's (LV) incredible efficiency is yet to be explained. It also has the unique ability to translate 15% linear sarcomere shortening into ejection fraction of more than 50% and wall thickening of more than 30% [1]. These properties are attributed mostly to the complex structure of the mammalian heart.

### 1.1. The mammalian heart structure

Senac [2] observed more than 250 years ago that in the LV of the mammalian heart, the epicardial and endocardial fibers are aligned longitudinally and the mid-ventricular fibers are aligned circumferentially. Extensive anatomical studies, in both animal and man, have verified that fiber angles vary in a smooth manner from a left-handed helix at the sub-epicardium to a right-handed helix at the sub-endocardium [3-5]. The macro-structure

of the heart was further revealed by Torrent-Guasp [6], who proposed a structure of a 'ventricular myocardial band' as the basis for describing the mammalian heart. This structure is a single muscular band, which is comprised of myocardial fibers.

The micro-organization of the myocardial tissue may be characterized in part by the orientation of the individual fibers, separated by the extra-cellular matrix. The tissue is also characterized by the "sheet" arrangements of multiple myocytes, separated by extensive "sheet cleavage" planes [7, 8]. In spite of this structured layout, the extra-cellular matrix provides continuity of the mechanical properties, by attaching the myocardial fibers together. Thus, the direction of the principal strain within the myocardial layers does not follow the fiber orientation [9].

### 1.2. The twist motion of the heart

The inclination of the different layers in the myocardium produces the complex movement of the LV, where the base and apex rotate in opposite directions and the equatorial plane serves as a transitional zone. This antagonistic twist of the apex versus the base is defined as the torsion of the LV and was described as 'wringing the wet towel' [5].

The LV torsion is described as a non-uniform movement, in both the longitudinal [10-15] and the transmural directions [11-15]. These non-uniformities are essential for the equalization of the mechanical parameters as well as for the distribution of energy demand across the myocardium [15]. Moreover, the systolic torsion tends to equalize sarcomere shortening and mechanical loading between the endocardial and epicardial layers of the LV [16-19]. The longitudinal nonuniformity is expressed as an increased torsion and transmural gradient from the base towards the apex, when the transmural gradient is expressed as the endocardial twist angle exceeding the epicardial angle.

### 1.3. Twist in disease

Different parameters may be derived from the twist motion, which may characterize or even quantify LV function. For instance, the peak rotation is a parameter that may describe the quality of the contractility: Since the contractility generates the rotation movement, then when the peak rotation parameter is reduced, one can assume that the LV has a systolic dysfunction caused by some pathology. An excellent example of such a case is chronic heart failure, in which this parameter is severely depressed [24].

Another interesting parameter is the “time to peak rotation”. This parameter provides information concerning the beginning of the diastole. If a delay occurs in the time to peak rotation, as reported for the case of aortic stenosis, even at its early stages [22,23], the untwist action invades the filling phase. Normally, the untwist action takes place during the isovolumic relaxation, and if it is prolonged to the filling phase, a diastolic dysfunction probably exists.

An additional parameter, which is related to the diastolic function, is the “time constant of relaxation”. This parameter was found to be well correlated to the time constant of the rapid untwist [25]. It was reported that during the first stage of acute cardiac allograft rejection, the rapid untwist slope is decreased [10, 20, 21].

## 2. Methods

10 normal subjects underwent an echocardiography study (after signing the informed consent form, as determined by the IRB) at the clinic for internal medicine and cardiology, Vinzenz-hospital, Köln. The ultrasound cine-loops, each of one heart cycle in duration (frame rate 76), were captured by a VIVID VII ultrasound imaging system (GE Healthcare, Inc.). The ultrasound cines were post-processed using the "Echo Pack" workstation (GE Healthcare, Inc.), installed with a specific and novel “2D Strain” software. This software uses a computerized eyeballing (CEB) algorithm [26], which provides 2D velocities and location at each “tracking point” (TP), in each frame of the cine-loop. Usually, there are 4x52 TPs associated with a myocardial cross-section. The velocity values serve as the basis for the LV rotation calculation.

In order to achieve a better spatial resolution, the noisy velocities of the TPs required a smoothing process. It was important that the relevant information was preserved despite the smoothing, specifically in the transmural direction (which contains only 4 data points). Therefore, 3D wavelet filtration, in both time and space, was utilized [27].

The smoothed velocities at each TP -  $V_x(x,y,t)$  and  $V_y(x,y,t)$ , were used for calculating the rotation: The

velocities of each TP underwent rotation in order to estimate the circumferential velocity  $V_c(x,y,t)$  as demonstrated in Fig. 1, where the direction of  $V_c(x,y,t)$  was defined as perpendicular to the local radius of that TP. The local radius was defined as the vector between each TP and the center of mass. The angular velocity,  $\omega(x,y,t)$ , was calculated by dividing  $V_c(x,y,t)$  by the local radii, at each TP. Eventually, the local rotation angle at each TP was calculated by time integration of the angular velocity.

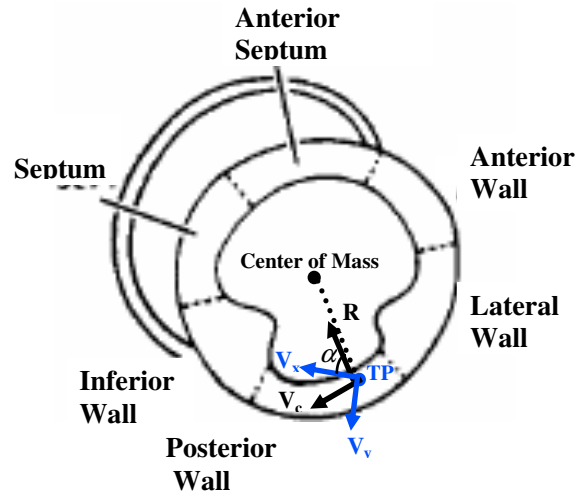


Figure1. Sketch of LV short-axis cross-section and the velocities that are evaluated by the algorithm.

## 3. Results

### 3.1. Tissue mimicking phantom results

In order to confirm that the spatial resolution is sufficient for distinguishing between the myocardial layers, the new method was applied to data acquired from a rotating tissue mimicking phantom that included a rotating cylinder within a static “tissue”. The region of interest was positioned so that 2 out of the 4 lines of the TP grid, as seen in Fig. 2, were located on the rotating cylinder, while the two outer lines were located on the static part of the phantom, and thus were not supposed to rotate.

It can be seen (Fig. 2, lower plot) that the inner layers register rotation, while the outer layers do not rotate. The standard deviation of the error (between the real values and the evaluated ones) was 0.05 degrees.

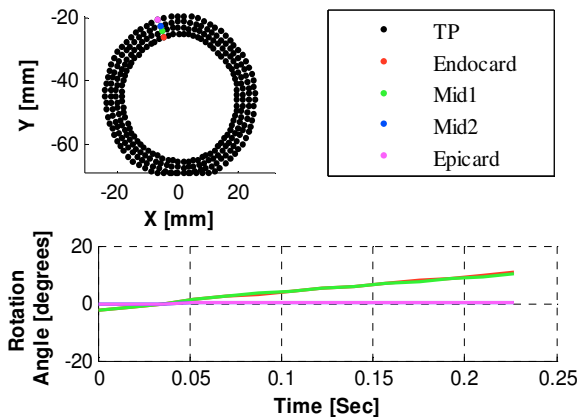


Figure 2. Results from a tissue mimicking phantom, which includes an inner rotating cylindrical and a static outer cylinder. The upper plot shows the TP positions in mm. The two inner layers are located on the rotating cylinder and the two outer layers are located on a static cylinder, and thus do not rotate.

### 3.2. Clinical results

Table 1 summarizes the results from the study that included 10 normal human subjects. The results are given for the six segments of the LV short-axis, shown in Fig. 1, and for three myocardial layers.

The results presented in Table 1 allow one to conclude that the inner layers rotate more than the outer layers. Moreover, the largest rotation occurs at the posterior wall, and it gets smaller as towards the septum.

The heterogeneity is well seen in the M-mode maps as depicted in Fig. 3.

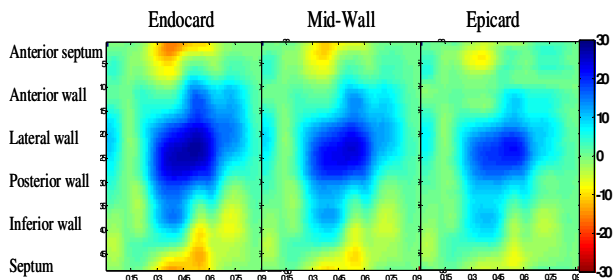


Figure 3. M-mode maps of the rotation at the different myocardial layers and at the different segments of the LV cross-section. Red represents counterclockwise rotation and blue represents clockwise rotation. The rotations are represented in three anatomical layers, Endocardium, midwall and Epicardium. The abscissa axis depicts the time [sec], and the ordinate axis represents the segments, as marked at the left hand side.

	Endocard	Midwall	Epicard
Ant septum	$-3.0 \pm 5.0$	$-1.9 \pm 4.7$	$-1.3 \pm 4.5$
Anterior	$3.8 \pm 4.4$	$2.0 \pm 3.2$	$1.4 \pm 2.9$
Lateral	$13.8 \pm 7.0$	$12.4 \pm 5.5$	$10.8 \pm 4.9$
Posterior	$21.0 \pm 5.4$	$18.3 \pm 4.9$	$16.6 \pm 3.9$
Inferior	$10.0 \pm 6.1$	$9.2 \pm 5.6$	$8.4 \pm 5.1$
Septum	$-1.9 \pm 3.8$	$-0.8 \pm 3.4$	$-0.5 \pm 2.9$

Table 1. Mean value of end systolic rotation  $\pm$  standard deviation [degrees], measured from apical LV short-axis cross-sections of 10 normal subjects.

## 4. Discussion

In this paper a novel method is presented, which allows evaluation of myocardial rotation. The novelty of this method is the high temporal and spatial resolution of the rotation mapping that shows the nonuniformity of the apical movement. Similar resolutions have been obtained before by tagged-MRI imaging [11, 12, 13], but this technique is not really available in most clinical settings, and too expensive for screening, early diagnosis and routine check-ups. Ultrasound techniques have been available for some time: most are based on Doppler measurements, thus restricted to just a few regions within the image (and LV cross-section). The more recent STI method, which is also based on B-mode images tissue tracking, was already used by Notomi to measure the myocardial rotation [28]. The STI method, though, has no resolution in the transmural direction. The main advantage of the method presented here is its high resolution, that allows measurements at several layers across the myocardial wall. Moreover, the resolution in the circumferential direction and the temporal resolution were also improved, due to improved filtration achieved by using suitable wavelet functions smoothing instead of the spline smoothing [28].

The main limitation of the technique is the out-of-plan motion of the LV slice, which occurs due to the heart motion, while the ultrasound scans were performed in 2D space. This limitation can be solved by using 3D scans instead of the 2D ones. Such a study is currently underway.

## Acknowledgements

This study was partly funded by the Chief Scientist, the Ministry of Industry and Commerce Magnetron project, and the Technion VP for Research. The authors are grateful for this support.

## References

- [1] Spotnitz HM. Macro design, structure and mechanics of the left ventricle. *J Thorac Cardiovasc Surg* 2000;119:1053–77.
- [2] Senac de JB: *Traite de la structure du Coeur, de son Action et de ses Maladies*, V 1. Paris, J. Vincent, 1749.
- [3] Torrent-Guasp F, Kocica MJ, Corno A, et al. Towards new understanding of the heart structure and function. *Eur J Cardiothorac Surg* 2005; 27:191:201
- [4] Streeter DD, Spotnitz HM, Patel DJ, Ross J, Sonnenblick EH. Fiber orientation in the canine left ventricle during diastole and systole. *Circ Res* 1969;24:339–47.
- [5] Buckberg GD. Basic science review: the helix and the heart. *J Thorac Cardiovasc Surg* 2002;124:863–83.
- [6] Torrent-Guasp F, Kocica MJ, Corno A, et al. Systolic ventricular filling. *Eur J Cardiothorac Surg* 2004;25:376–86.
- [7] Arts T, Costa KD, Covell JW, McCulloch AD. Relating myocardial laminar architecture to shear strain and muscle fiber orientation. *Am J Physiol Heart Circ Physiol.* 2001 May;280(5):H2222-9. Costa KD, Takayama Y, McCulloch AD, Covell JW. Laminar fiber architecture and three-dimensional systolic mechanics in canine ventricular myocardium. *Am J Physiol.* 1999 Feb;276(2 Pt 2):H595-607.
- [8] Waldman LK, Nosan D, Villarreal F, Covell JW. Relation between transmural deformation and local myofiber direction in canine left ventricle. *Circ Res.* 1988 Sep;63(3):550-62.
- [9] Hansen, D. E., G. T. Daughters, E. L. Alderman, N. B. Ingels, and D. C. Miller. Torsional deformation of the left ventricular midwall in human hearts with intramyocardial markers: regional heterogeneity and sensitivity to the inotropic effects of abrupt rate changes. *Circ. Res.* 62: 941-952, 1988.
- [10] Buchalter, M. B., J. L. Weiss, W. J. Rogers, E. A. Zerhouni, M. L. Weisfeldt, R. Beyar, and E. P. Shapiro. Noninvasive quantification of left ventricular rotational deformation in normal humans using magnetic resonance imaging myocardial tagging. *Circulation* 81: 1236-1244, 1990.
- [11] Maier SE, Fischer SE, McKinnon GC, Hess OM, Krayenbuehl HP, Boesiger P. Evaluation of left ventricular segmental wall motion in hypertrophic cardiomyopathy with myocardial tagging. *Circulation.* 1992;86:1919 – 1928.
- [12] Young AA, Kramer CM, Ferrari VA, Axel L, Reichek N. Three-dimensional left ventricular deformation in hypertrophic cardiomyopathy. *Circulation.* 1994 Aug;90(2):854-67.
- [13] Azhari H, Buchalter M, Sideman S, Shapiro E, Beyar R. A conical model to describe the nonuniformity of the left ventricular twisting motion. *Ann Biomed Eng.* 1992;20(2):149-65.
- [14] Beyar R, Sideman S. Effect of the twisting motion on the nonuniformities of transmyocardial fiber mechanics and energy demand. *IEEE Trans Biomed Eng.* 1985 Oct;32(10):764-9.
- [15] Arts T, Reneman RS. Dynamics of left ventricular wall and mitral valve mechanics. *J Biomech.* 1989;22(3):261-71.
- [16] Guccione JM, McCulloch AD, Waldman LK. Passive material properties of intact ventricular myocardium determined from a cylindrical model. *J Biomech Eng.* 1991 Feb;113(1):42-55.
- [17] Bovendeerd PH, Arts T, Huyghe JM, van Campen DH, Reneman RS. Dependence of local left ventricular wall mechanics on myocardial fiber orientation: a model study. *J Biomech.* 1992 Oct;25(10):1129-40.
- [18] Vendelin M, Bovendeerd PH, Engelbrecht J, Arts T. Optimizing ventricular fibers: uniform strain or stress, but not ATP consumption, leads to high efficiency. *Am J Physiol Heart Circ Physiol.* 2002 Sep; 283(3):H1072-81.
- [19] Ingels, N. B., D. E. Hansen, G. T. Daughters, E. B. Stinson, E. L. Alderman, and D. C. Miller. Relation between longitudinal, circumferential, and oblique shortening and torsional deformation in the left ventricle of the transplanted human heart. *Circ. Res.* 64: 915-927, 1989.
- [20] Yun, K. L., M. A. Niczyprouk, G. T. Daughters, N. B. Ingels, E. B. Stinson, E. L. Alderman, D. E. Hansen, and D. C. Miller. Alterations in left ventricular diastolic twist mechanics during acute human cardiac allograft rejection. *Circulation* 83: 962-973, 1991.
- [21] Stuber M, Scheidegger MB, Fischer SE, Nagel E, Steinemann F, Hess OM, and Boesiger P. Alterations in the local myocardial motion pattern in patients suffering from pressure overload due to aortic stenosis. *Circulation* 100: 361–368, 1999.
- [22] Nagel E, Stuber M, Burkhard B, Fischer SE, Scheidegger MB, Boesiger P, Hess OM. Cardiac rotation and relaxation in patients with aortic valve stenosis. *Eur Heart J.* 2000 Apr;21(7):582-9.
- [23] Fuchs E, Muller MF, Oswald H, Thony H, Mohacsi P, Hess OM. Cardiac rotation and relaxation in patients with chronic heart failure. *Eur J Heart Fail.* 2004 Oct;6(6):715-22.
- [24] Dong SJ, Hees PS, Siu CO, Weiss JL, and Shapiro EP. MRI assessment of LV relaxation by untwisting rate: a new isovolumic phase measure of tau. *Am J Physiol Heart Circ Physiol* 281: H2002–H2009, 2001.
- [25] Rappaport D., Adam D., Lysyansky P., Riesner, S. Assessment of Myocardial Regional Strain and Strain Rate by Tissue Tracking in B-Mode Echocardiograms, *Ultrasound in Med. & Biol*, Vol. 32, No. 8, pp. 1181–1192, 2006.
- [26] Vitek N. Quantifying the spatial and temporal distribution of myocardial strain by ultrasound. M.Sc. thesis, Technion, Haifa, 2006.
- [27] Notomi Y, Lysyansky P, Setser RM, Shiota T, Popovic ZB, Martin-Miklovic MG, Weaver JA, Oryszak SJ, Greenberg NL, White RD, Thomas JD. Measurement of ventricular torsion by two-dimensional ultrasound speckle tracking imaging. *J Am Coll Cardiol.* 2005 Jun 21;45(12):2034-41.

Address for correspondence:

Noa Bachner  
Department of Biomedical Engineering  
Technion – Israel Institute of Technology  
Haifa, 32000, Israel  
[noab@tx.technion.ac.il](mailto:noab@tx.technion.ac.il)