

Modeling Human Ventricular Geometry and Fiber Orientation Based on Diffusion Tensor MRI

G Seemann, DUJ Keller, DL Weiss, O Dössel

Institute of Biomedical Engineering, Universität Karlsruhe (TH), Karlsruhe, Germany

Abstract

Accurate numerical simulations of the electrical and mechanical activities of the heart require suitable anatomical models including muscle fiber orientation. In this work, a model based on diffusion tensor imaging delivering both geometrical information and fiber orientation was developed. The dataset was segmented into a variety of tissue classes including fiber orientation information in the two ventricles. A tool was generated allowing to extract the fiber orientation information at different parts of the ventricles. These data is compared to histological measurements. The extracted data show good agreement with the histological in the left ventricular free wall. A transmurally constant transversal angle of fiber as proposed by the histological data was not seen in the extracted data.

1. Introduction

Computational models of the human heart are of interest in cardiology, eg. for simulations of excitation conduction and mechanical deformation in order to enhance the understanding of the fundamental cardiac processes. To date, the underlying anatomical models of high accuracy were constructed based on medical images using digital image processing. Beyond focussing on the model's geometry it is important to account eg. for regional heterogeneity of the myocytes. Furthermore, the myocardium has anisotropic electrical and mechanical properties depending on the muscle fiber orientation. Up to now, rule-based approaches relying primarily on histological measurements [1] have been used to include fiber orientation in cardiac electromechanical simulations.

In this work, an anatomical model of the human ventricles was constructed using diffusion tensor (DT) MRI data. This measures the fiber orientation together with geometrical information non-destructively gained by a MRI signal caused by the diffusion of water in a specialized DTMRI sequence. DTMRI is able to reconstruct the myofiber anatomy at a resolution 1 to 2 orders of magnitude greater than histological measurements [2, 3].

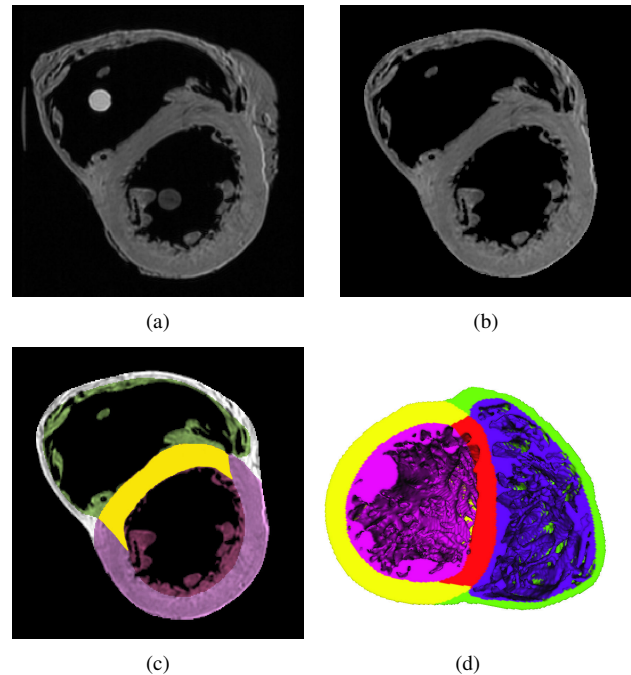


Figure 1. Geometrical model based on the CCBM dataset. (a) Original data including holding devices and remnants of the pericardium. (b) Data after preprocessing containing only musculature structures. (c) Segmented data: different colors indicate left and right ventricle as well as papillary muscles and the ventricular septum. (d) Sliced ventricles at mid cavity height in a 3D view.

2. Methods

DTMRI is based on the principal that water being unrestricted by a membrane diffuses preferentially in the direction of the long axis of a muscle fiber. This long axis is described in a vectorial form by the diffusion weighted imaging sequence. Recent studies have shown a strong correlation between histological measurements and DTMRI-acquired fiber orientation [2, 3].

Imaging of the dataset was performed at the Center for Cardiovascular Bioinformatics and Modeling (CCBM)

at the Johns Hopkins University in Baltimore, Maryland (fig. 1 (a)). An explanted human heart was fixed using an isotonic formaldehyde solution to prevent possible flow artefacts. The dataset was imaged using a 3D fast spin echo DTMRI imaging sequence with 19 magnetic gradient directions at room temperature. It consists of 13 parts: a normal MRI recording, 3 datasets for the eigenvalues in each direction and 9 datasets for the cartesian components of the corresponding eigenvectors. Initial resolution was $256 \times 256 \times 134$ voxel with a size of $0.4297 \text{ mm} \times 0.4297 \text{ mm} \times 1 \text{ mm}$. Figure 2 illustrates the fiber orientation variation in 3 exemplary slices of the left ventricle.

Segmentation of the dataset was performed by a combination of semi-automatic and manual methods of digital image processing. These techniques were region growing and interactively deformable triangle meshes as well as manual methods to stabilize the other two methods.

Fiber orientation influences electrical excitation conduction and mechanical activity. Streeter [1] extracted the transmural course of the fiber orientation from a block of tissue from an excised human heart. The fiber orientation is described by the helix angle α_1 and transverse angle α_3 . No noticeable change in α_3 was measured despite a small change of 6° from apex to base. α_1 was constantly varying from epicardium (-75.3°) over 0° in midmyocardium to 55.5° in endocardium (fig. 4 (d)).

In order to extract new rules describing the fiber orientation of the CCBM dataset, the determination of reproducible and robust subdivisions in the ventricles was necessary. The subdividing was based on a publication from the American Heart Association (AHA) [4], suggesting a standardized myocardial fragmentation into 17 segments and nomenclature procedure for tomographic imaging data of the heart (fig. 3 (a)).

3. Results

The first step for the segmentation was the removal of the holding devices and remnants of the pericardium (fig. 1 (b)). The holding devices which were used to stabilize the heart prior to the polymerization of the fixative were deleted using a region growing approach. Additionally, remnants of grease and the pericardium were cut off and a part of the apex which was missing due to an aliasing effect was reconstructed with the help of an interactively deformable triangle mesh. Then, different cardiac tissue classes were assigned to left and right ventricle, left and right papillary muscles, the ventricular septum and the blood of the left and right cavity (fig. 1 (c)). It is noticeable that the septum has an own tissue class to account for recent reports in the literature stating a different ion channel distribution and behaviour in the septum compared to the right and left ventricle [5]. Figure 1 (d) illustrates the three-dimensional model of the ventricles in a sliced view.




Figure 2. 3 short-axis slices from a basal, equatorial and apical part of the left ventricle. (a) Imbrication of fibers close to the epicardial border can be seen in all 3 slices. (b) Lateral view of the 3 slices is presented to give an impression concerning their position in the left ventricle.

The anisotropic voxel dimensions were interpolated to a cubic size of 0.2 mm by means of a linear algorithm for both the geometrical model and the fiber orientation information of the CCBM data. Exemplary short-axis slices of the fiber orientation distribution is shown in fig. 2 from a basal, equatorial and apical part of the left ventricle. The data illustrates that the transversal angle has a non-zero component at the endocardial and epicardial boundary indicating that fibers are not perfectly parallel to the borders at those zones.

After the interpolation, vector components of the DTMRI data were transformed from cartesian to local coordinates in order to compare extracted fiber orientations with the histological data of Streeter. The transmural direction was found by constructing the normal vector on the epicardial surface.

A software tool was created to automatically divide the left ventricle into several subdivisions. A standard subdivision is given by the AHA in their myocardial segmentation guidelines [4]. Figure 3 (b) shows the AHA segmentation

of the left ventricle of the CCBM model. In order to extract fiber orientation in the left ventricle in a more general way, the software tool was enhanced. A free choice of parts in the x-y plane as well as slices in the x-z plane is possible (see fig. 4). As a good number of segments for the extraction of fiber orientations the fractioning in 10 parts in the x-y plane and 10 slices in the x-z plane has been identified. Figure 4 (a) illustrates these subdivisions in a schematic way.

The helix (α_1) and transverse angle (α_3) for two exemplary situations were plotted in fig. 4 (b,c) and (e,f), respectively. Figure 4 (b,c) shows the two angles for all 10 segments of the x-z plane for part 3 in the x-y plane. α_1 in fig. 4 (b) is decreasing nearly linearly from endocardium (38°) to endocardium (-34°) for all parts from base (#1) to apex (#10). Figure 4 (d) shows in comparison the data Streeter gained by histological measurements. Compared to Streeter's data, α_3 is varying from endocardium to epicardium (fig. 4 (c)). Additionally, this variation is changing from base (#1) to apex (#10). In basal regions, α_3 is positive and decreasing from endocardium to epicardium. In apical regions it is vice versa.

Figure 4 (e,f) shows the two angles α_1 and α_3 for all 10 part of the x-y plane for slice 5 in the x-z plane. Both angles show good agreement with Streeter's histological data. α_1 is continuously decreasing from endocardium (41°) to epicardium (-43°) and α_3 is nearly constant around 0° in all parts of the slice in the left ventricle.

4. Discussion and conclusions

The developed high resolution model of the human ventricles consists of information combining both anatomical data and muscle fiber orientation. Several rules were derived describing fiber orientation in different regions of the heart in contrast to the simple rule-based approach used before.

In contrast to other MRI based ventricular geometries, this dataset has the disadvantage that it is based on an explanted heart. But previous studies suggested that fixation is not influencing the overall shape significantly [2, 3]. Due to the long lasting imaging procedure the data has the advantage of having a very high spatial resolution giving lots of detail especially in the papillary muscles. In a previous study we identified similar advantages and disadvantages in a dataset of canine ventricle [6].

The extracted fiber orientation in different regions of the left ventricle showed that the orientation of fibers is more complex than suggested by the histological data of Streeter. The helix angle α_1 does match very well in all parts of mid-cavital regions but differs at apical and basal regions (data not shown). The largest difference between the DTMRI data and the histological measurements was found in the transversal angle α_3 . It was proposed to be

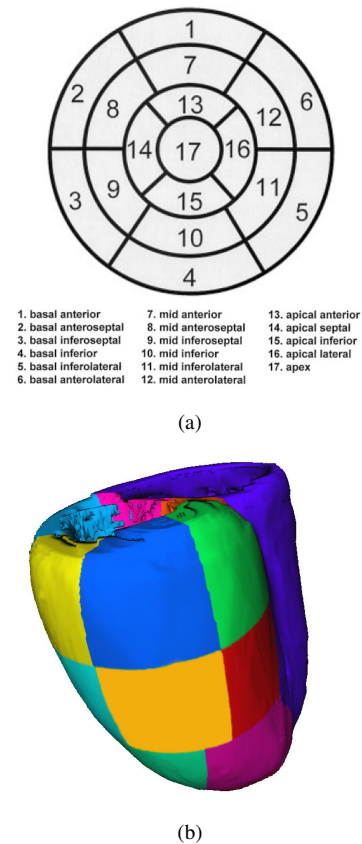


Figure 3. Constructed subdivisions of the geometrical model. (a) The nomenclature of the 17 segments according to AHA [5]. (b) Automatically subdivided left ventricle of the CCBM dataset according to the AHA suggestion.

constant in the histological data but was varying from endocardium to epicardium as well as from apex to base in the DTMRI data. This variation was also seen in rabbit and canine DTMRI data [3]. The question whether a non-zero transverse angle exist at the epicardial border could not be finally answered since other structures like blood vessels or the extracellular matrix might influence the fiber orientation at the boundaries.

In case of the right ventricle, the evaluation of the fiber orientation is much more difficult, as reports of systematic measurements of both helix and transverse angle are lacking in the literature. The limited resolution of the dataset, which proved sufficient for extracting information on the left ventricle, was too poor to achieve high quality results in the much thinner right ventricle.

The new fiber orientation rules derived from the left ventricle of the CCBM dataset can be used to define accurate anisotropic features in anatomical structures based on images like CT data with no fiber orientation information. The transferable fiber orientation will help to increase the

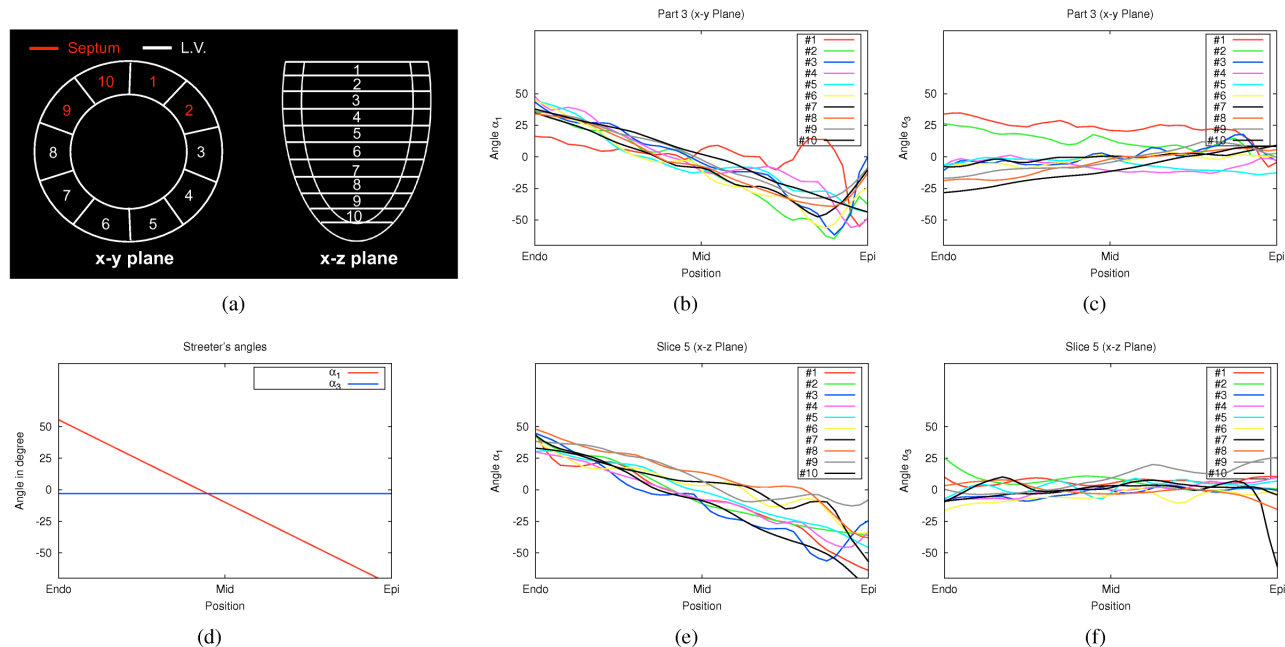


Figure 4. DTMRI acquired fiber orientation at different subdivisions in the left ventricle. (a) The left ventricle is subdivided into 10 parts in the x-y and into 10 slices in the x-z plane. The red-colored subdivisions are part of the septum. Transmural course of the helix α_1 (b) and transverse angle α_3 (c) in part 3 of the x-y plane at all x-z segments. (d) Extracted course of the helix (α_1) and transverse angle (α_3) based on the measurement data of Streeter [1]. Transmural course of the helix α_1 (e) and transverse angle α_3 (f) in slice 5 of the x-z plane at all corresponding x-y segments.

precision of both deformation and excitation conduction simulations and will help to understand the influence of fiber orientation on electrical and mechanical function, especially in regions where the DTMRI technique gains different fiber directions compared to previously published histological data.

Acknowledgements

The authors thank Drs. Patrick A. Helm and Raimond L. Winslow at the Center for Cardiovascular Bioinformatics and Modeling and Dr. Elliot McVeigh at the National Institute of Health for providing the DTMRI data.

References

- [1] Streeter DD. Gross morphology and fiber geometry of the heart. In Bethesda B (ed.), *Handbook of Physiology: The Cardiovascular System*, volume I. American Physiology Society, 1979; 61–112.
- [2] Hsu EW, Muzikant AL, Matulevicius SA, Penland RC, Henriquez CS. Magnetic resonance myocardial fiber-orientation mapping with direct histological correlation. *Am J Physiol* 1998;274(43):H1627–H1634.
- [3] Scollan D. Reconstructing the heart: Development and application of biophysically-based electrical models of propa-

gation in ventricular myocardium reconstructed from diffusion tensor MRI. Ph.D. thesis, Johns Hopkins University Baltimore, Maryland, May 2002.

- [4] Cerqueira M, Weissman N, Dilsizian V, Jacobs A, Kaul S, Laskey W, Pennell D, Rumberger J, Ryan T, Verani M. Standardized myocardial segmentation and nomenclature for tomographic imaging of the heart: A statement for healthcare professionals from the cardiac imaging committee of the council on clinical cardiology of the american heart association. *Circulation* 2001;105:539–542.
- [5] Brunet S, Aimond F, Li H, Guo W, Eldstrom J, Fedida D, Yamada KA, Nerbonne JM. Heterogeneous expression of repolarizing, voltage-gated k^+ currents in adult mouse ventricles. *J Physiol* Aug. 2004;15(559):103–120.
- [6] Sachse FB, Henriquez C, Seemann G, Riedel C, Werner CD, Penland RC, Davis B, Hsu E. Modeling of fiber orientation in the ventricular myocardium with MR diffusion imaging. In *Proc. Computers in Cardiology*, volume 28. 2001; 617–620.

Address for correspondence:

Dr. Gunnar Seemann
 Institut für Biomedizinische Technik
 Universität Karlsruhe (TH)
 Kaiserstr. 12, 76131 Karlsruhe, Germany
 Gunnar.Seemann@ibt.uni-karlsruhe.de