

Diagnosis of Brain Abnormality Using both Structural and Functional MR Images

Yong Fan, Hengyi Rao, Joan Giannetta, Hallam Hurt,
Jiongjiong Wang, Christos Davatzikos, and Dinggang Shen

Abstract— A number of neurological diseases are associated with structural and functional alterations in the brain. This paper presents a method of using both structural and functional MR images for brain disease diagnosis, by machine learning and high-dimensional template warping. First, a high-dimensional template warping technique is used to compute morphological and functional representations for each individual brain in a template space, within a mass preserving framework. Then, statistical regional features are extracted to reduce the dimensionality of morphological and functional representations, as well as to achieve the robustness to registration errors and inter-subject variations. Finally, the most discriminative regional features are selected by a hybrid feature selection method for brain classification, using a nonlinear support vector machine. The proposed method has been applied to classifying the brain images of prenatally cocaine-exposed young adults from those of socioeconomically matched controls, resulting in 91.8% correct classification rate using a leave-one-out cross-validation. Comparison results show the effectiveness of our method and also the importance of simultaneously using both structural and functional images for brain classification.

I. INTRODUCTION

Magnetic resonance (MR) imaging has been playing an important role in neuroscience research to examine brain conditions related to normal and abnormal brain structures and functions in vivo. Besides region of interest (ROI) analysis that generally requires good *a priori* hypothesis about the problem under study, whole brain analysis methods have been increasingly utilized to explore the morphological and functional brain changes rendered by neurological factors [1, 2]. The success of these analysis methods in examining brains has motivated researchers to explore an inverse problem, i.e., brain classification using MR images and multivariate analysis.

MR brain image classification is typically solved by

standard pattern recognition methods, with steps of feature extraction, feature dimensionality reduction, and feature-based classification. Among these three steps, feature extraction is a crucial step. Once effective features have been extracted, feature dimensionality reduction and feature-based classification can be straightforwardly completed by using suitable methods developed in machine learning area. For example, for feature dimensionality reduction, principal component analysis (PCA) and feature selection techniques can be used [3-6], whereas for classification, the support vector machine (SVM) based classifier or the linear discrimination analysis method can be applied [6, 7].

Voxel-wise features have been widely used as extracted features for MR brain image classification [3, 6, 8, 9]. These voxel-wise features are typically computed from the normalized individual brain images in a template space, or the deformation fields that bring those individual brain images into the template. Generally, nonrigid registration is performed for structural images, while linear registration is performed for functional images. However, such voxel-wise features are sensitive to registration errors and inter-subject variations of structure and function, particularly for functional image analysis as indicated in [10]. On the other hand, it is known that the brain alterations resulting from pathological processes usually occur not in isolated spots, but in regions, although their positions and shapes are generally not known in advance. This implies that we should extract features from the regions with voxels of similar correlation to diseases, i.e., obtaining regional features that are robust to noise, registration error, and inter-subject variation [5, 11].

In this paper, we study a patient classification problem, i.e., separating prenatally cocaine-exposed young adults from socioeconomically matched normal controls based on their brain images, *with a goal of achieving a quantitative diagnosis that is currently relying only on self-report*. Several studies based on animal model have revealed that prenatal cocaine exposure has an enduring impact on the neurocognitive development, accompanied by potential structural and functional brain alterations [12]. Although a lot of promising results have been reported by the classification methods that focus on a single modality image, i.e., structural or functional MR images [3-9, 11], it is

Y. Fan, C. Davatzikos, and D. Shen are with the Section of Biomedical Image Analysis (SBIA), Department of Radiology, University of Pennsylvania, 3600 Market Street, Suite 380, Philadelphia, PA 19104, USA. (e-mails: {yong.fan, dinggang.shen}@uphs.upenn.edu)

H. Rao and J. Wang are with Department of Neurology, Center for Functional Neuroimaging, University of Pennsylvania, 3 W Gates, 3400 Spruce Street, Philadelphia, PA 19104, USA.

J. Giannetta and H. Hurt are with Department of Pediatrics, Division of Neonatology, The Children's Hospital of Philadelphia, 3535 Market Street, 15th Floor, Philadelphia, PA 19104, USA.

potentially advantageous of using both structural and functional images for diagnosing brain diseases which generally manifest pathological changes in both imaging modalities. Accordingly, in this paper, we present a comprehensive framework for brain classification, based on both structural and functional MR images of brain. Particularly, in our method, regional features are effectively extracted from both structural and functional MR images, and the most discriminative ones are determined by a hybrid feature selection technique for brain classification by a support vector machine.

II. METHODS

A. Data Description and Preprocessing

This study has been approved by the local Ethics Committee. After giving informed consent, forty nine subjects participated in this study, including 25 prenatal cocaine exposed patients (11 females, mean age 14.8 ± 1.1 years, range from 13 to 16 years) and 24 socioeconomically matched normal controls (13 females, mean age 14.3 ± 1.2 years, range from 13 to 16 years). Both structural and functional scans of all the subjects were obtained from a Siemens 3.0T Trio scanner. The high-resolution structural scans were obtained by a 3D MPRAGE sequence with TR=1620ms, TI=950ms, TE=3ms, flip angle=15°, 160 contiguous slices of 1.0 mm thickness, FOV=192 x 256 mm², matrix =192 X 256. The functional scans of resting brain were obtained by an amplitude-modulated continuous arterial spin labeling (CASL) perfusion technique (16 slices, 6mm thk/1.5mm sp, TR: 4s, Labeling time: 2s, Delay time: 1.2s, TE: 17 ms, FOV: 22 x 22cm², Matrix: 64 x 64). Eighty perfusion weighted images for each subject were obtained in a 320s scan.

The Statistical Parametric Mapping (SPM) software package was used to correct MR image series for head movements. Perfusion weighted image series were then generated by pair-wise subtraction of the label and control images, followed by conversion to absolute cortical blood flow (CBF) image series based on a single compartment CASL perfusion model [13]. For each subject, one single mean CBF image, termed as *functional image* in the following, was generated and further co-registered with its high resolution structural image.

For direct comparison of brains across different subjects, all subjects are spatially normalized to one of the subjects chosen as a template, by registering their structural images with the template's structural image [14]. Functional images are directly warped to the template space by the deformation fields estimated for their corresponding structural images, since functional images have been co-registered with corresponding structural images. Thus, the morphological and functional representation of each subject in the template space can be obtained, i.e., three local feature maps,

respectively termed as white matter (WM) tissue density map m_1 , gray matter (GM) tissue density map m_2 , and functional feature map m_3 , as detailed next.

GM and WM tissue density maps are obtained for each subject by first segmenting each structural MR image into three tissues, i.e., GM, WM, and cerebrospinal fluid (CSF), and then warping these tissue maps into the template space in a mass-preserving way [15], which is achieved by increasing the respective density when a region is compressed, and vice versa. As a result, three tissue density maps are generated in the template space, each reflecting local volumetric measurements corresponding to GM, WM, and CSF, respectively. In this study, only GM and WM tissue density maps (m_1 and m_2) are used for brain classification. On the other hand, functional feature map (m_3) is actually the warped CBF image of each subject in the template space, with the total CBF volume preserved in any arbitrarily defined region during the warping procedure.

B. Feature Extraction

For each individual brain, the regional features will be respectively extracted from each feature map defined above, and all extracted regional features from its three feature maps are concatenated into a long feature vector to completely represent the structural and functional profile of this individual brain in the template space.

To extract regional features from feature map m_i , a statistical regional feature extraction method is utilized [5, 11]. First, brain regions are generated by adaptively partitioning the template space into a number of separate regions according to the similarity of correlations between voxel-wise features of m_i and classification labels (clinical variable), by a watershed segmentation method. To take into account the generalization ability of voxel-wise features in classifying unseen subjects, a leave-one-out cross-validation strategy is adopted to estimate the correlation. That is, given n training samples, the worst Pearson correlation coefficient resulting from n leave-one-out correlation measurements is selected as the overall correlation coefficient of each voxel-wise feature to class label. This correlation measurement for each voxel-wise feature is particularly important when examining a very large number of features; otherwise, outlier can be found just by a chance.

Then, to extract regional features from each above generated region and achieve robustness to inter-subject variations of structure or function within the region, the probability distribution of voxel-wise features within the region is captured by a histogram-based vector, which forms a statistical representation of this region. Obviously, the histogram-based feature vector is invariant to inter-subject spatial variations of structure or function within the region.

Finally, to robustly and efficiently compare the feature vectors in the same regions across different subjects, PCA is used to estimate a subspace of histogram-based feature

vectors in each region using all training subjects, and then each feature vector is represented by the coefficients in the subspace constructed. The regional features extracted by this method not only compactly represent the statistical information within each region for every subject, but also capture statistical variations of feature vectors across different subjects.

C. Hybrid Feature Selection and SVM Classification

By extracting a compact set of regional features from each automatically generated brain region, we can efficiently represent the brain images of each subject, i.e., by all regional features calculated from three feature maps, m_1 , m_2 , and m_3 . However, some regional features are less effective, irrelevant and redundant for classification, compared to others. Therefore, it is important to select a small set of most effective features, in order to improve the generalization ability and the performance of the finally constructed classifier. Thus, a hybrid feature selection algorithm [5] is used to select the most discriminative regional features for classification. In particular, we first use a correlation-based feature ranking method to select a set of the most relevant features, from which we further select a subset of features by a SVM-based subset feature selection algorithm [16].

Based on the regional features selected above, a nonlinear SVM [17] is employed for classification, since SVM has been proved in lots of studies to have superior performance on small sample problems. In this study, the Gaussian radial basis function kernel is used.

III. RESULTS

A. Classification Performance

A full leave-one-out cross-validation is performed to examine the performance of our proposed method in classifying brains. In each leave-one-out validation case, one subject was first selected as a testing subject, and the remaining subjects are used for adaptive regional feature extraction, feature selection, and classifier training, as described in Section 2. By repeatedly leaving each subject out as a testing subject, we obtained the average classification rate from 49 leave-one-out cases. The correct classification rate is 91.8%, using both structural and functional MR images of brains. To show the stability and the overall classification performance of our method, the classification rates with respect to the number of features used for classification and the kernel sizes used in SVM are shown in Fig. 1, along with a ROC curve of the classifier that yields the best classification result in Fig. 2. The area under the ROC curve is 0.91, indicating a relative good performance of our method.

The performance of brain classification has also been evaluated with respect to (1) different classification methods, i.e., our method and popular PCA-based

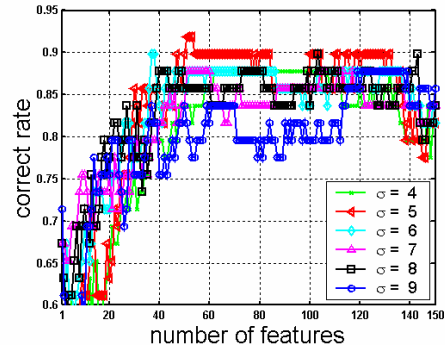


Fig.1. Classification rates with respect to the number of features used for classification and the kernel sizes used in SVM.

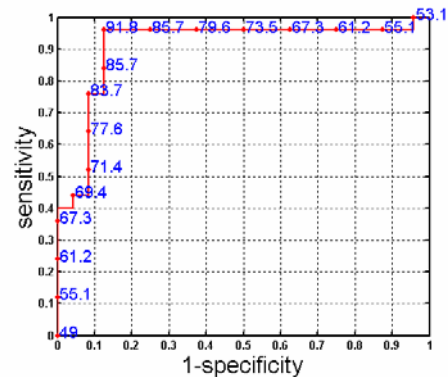


Fig.2. ROC curve of the classifier which yields the best classification rate. Numbers on the curve are the correct classification rates (%).The area under the ROC curve is 0.91.

classification method, and (2) different MR images used for classification, i.e., only structural MR images, or only functional MR images, or both of structural and functional MR images. Table 1 summarizes these classification results. It can be observed that the classification results by our method in the last row are much better than the respective ones by PCA-based classification. This should be contributed to the effectiveness of our regional feature extraction method, which can capture the relatively reliable and effective features for classification, compared to the PCA-based feature extraction method that is usually not effective for the small sample problem due to insufficient training. On the other hand, the use of both structural and function MR images produces the best results by using our method (91.8%), indicating the importance of simultaneously using both structural and functional images for examining brain alterations.

Table 1. Comparison on different classification methods (%).

Features \ Methods	Structural features	Functional features	Both features
PCA	63.3	77.6	75.5
Ours	87.8	87.8	91.8

B. Group Difference

Besides using the pattern analysis method to classify individual brains, we can also use it for detecting group differences in two brain sets. In [5, 18], the discriminative direction method was used to estimate the group difference from a built classifier. Here, we utilized a similar method to estimate the group difference. In particular, the overall group differences are constructed by averaging all group differences estimated from all leave-one-out experiments, thus representing the frequency and significance of group difference in the detected brain regions. Since three feature maps, i.e., functional feature map, and GM and WM tissue density maps, are used, the group differences detected from these three maps are overlaid on the template brain, respectively, as shown by left, middle, and right panels of Fig. 3. It can be observed that the most significant group differences were found in multiple brain areas including the bilateral insula and caudate nucleus, which are known to be involved in the processing of negative emotion and arousal [19].

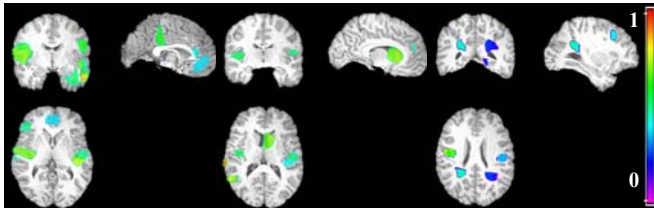


Fig.3. Regions of most representative of the group differences, detected from functional feature map, GM feature map, and WM feature map (from left to right), by a discriminative direction method. Here, high light indicates more significant.

IV. CONCLUSION

We have presented a brain classification method, to separate brain images of prenatally cocaine-exposed young adults from those of socioeconomically matched controls, using both structural and functional MR images. The experimental results have shown that the use of images from both modalities improves the classification accuracy by our method, compared to the cases of using only one modality images, i.e., structural MR images or functional MR images. Also, experimental results have shown that the proposed method performs better than PCA-based classification method, for any cases of using a single modality image or dual-modality images. This should be contributed to the proposed feature extraction method that collects from the automatically generated brain regions the statistical regional features, which are robust to registration error and inter-subject variation and have good generalization to unseen samples. Finally, the group differences found by our method provide unique and important cues about long-term effects of drug use during pregnancy on offspring.

REFERENCES

- [1] J. Ashburner and K. J. Friston, "Voxel-based morphometry: the methods," *Neuroimage*, vol. 11, pp. 805-821, 2000.
- [2] K. J. Friston, A. P. Holmes, K. Worsley, J. B. Poline, C. D. Frith, and R. S. J. Frackowiak, "Statistical parametric maps in functional imaging: a general linear approach," *Human Brain Mapping*, vol. 2, pp. 189-210, 1995.
- [3] D. D. Cox and R. L. Savoya, "Functional magnetic resonance imaging (fMRI) "brain reading": detecting and classifying distributed patterns of fMRI activity in human visual cortex," *NeuroImage*, vol. 19, pp. 261-270, 2003.
- [4] T. M. Mitchell, R. Hutchinson, R. S. Niculescu, F. Pereira, and X. Wang, "Learning to Decode Cognitive States from Brain Images," *Machine Learning*, vol. 57, pp. 145-175, 2004.
- [5] Y. Fan, D. Shen, and C. Davatzikos, "Classification of Structural Images via High-Dimensional Image Warping, Robust Feature Extraction, and SVM," presented at MICCAI, Palm Springs, California, USA, 2005.
- [6] J. Mourão-Miranda, A. L. W. Bokde, C. Born, H. Hampel, and M. Stetter, "Classifying brain states and determining the discriminating activation patterns: Support Vector Machine on functional MRI data," *NeuroImage*, vol. 28, pp. 980-995, 2005.
- [7] C. Davatzikos, K. Ruparel, Y. Fan, D. Shen, M. Acharyya, J. Loughhead, R. C. Gur, and D. Langleben, "Classifying spatial patterns of brain activity with machine learning methods: application to lie detection," *NeuroImage*, vol. 28, pp. 663-668, 2005.
- [8] J. Ford, H. Frarid, F. Makedon, L. A. Flashman, T. W. McAllister, V. Megalooikonomou, and A. J. Saykin, "Patient classification of fmri activation maps," presented at MICCAI03, 2003.
- [9] L. Zhang, D. Samaras, D. Tomasi, N. Alia-Klein, L. Cottone, A. Leskovjan, N. Volkow, and R. Goldstein, "Exploring temporal information in functional magnetic resonance imaging brain data," presented at MICCAI 2005, 2005.
- [10] B. Thirion, P. Pinel, and J.-B. Poline, "Finding landmarks in the functional brain: detection and use for group characterization," presented at MICCAI 2005, 2005.
- [11] Y. Fan, D. Shen, and D. Christos, "Decoding Cognitive States from fMRI images of Subjects by Machine Learning and Multivariate Classification," presented at IEEE Workshop on Mathematical Methods in Biomedical Image (MMBIA 2006), New York, 2006.
- [12] M. S. Lidow, "Consequences of prenatal cocaine exposure in nonhuman primates," *Developmental Brain Research*, vol. 147, pp. 23-36, 2003.
- [13] J. Wang, Y. Zhang, R. L. Wolf, A. C. Roc, D. C. Alsop, and J. A. Detre, "Amplitude modulated continuous arterial spin labeling perfusion MR with single coil at 3T-feasibility," *Radiology*, vol. 235, pp. 218-228, 2005.
- [14] D. Shen and C. Davatzikos, "HAMMER: Hierarchical attribute matching mechanism for elastic registration," *IEEE Transactions on Medical Imaging*, vol. 21, pp. 1421-1439, 2002.
- [15] C. Davatzikos, A. Genc, D. Xu, and S. M. Resnick, "Voxel-Based Morphometry Using the RAVENS Maps: Methods and Validation Using Simulated Longitudinal Atrophy," *NeuroImage*, vol. 14, pp. 1361-1369, 2001.
- [16] A. Rakotomamonjy, "Variable Selection using SVM-based criteria," *Journal of Machine Learning Research*, vol. 3, pp. 1357-1370, 2003.
- [17] V. N. Vapnik, *The Nature of Statistical Learning Theory (Statistics for Engineering and Information Science)*, 2nd edition ed: Springer-Verlag, 1999.
- [18] P. Golland, W. E. L. Grimson, M. E. Shenton, and R. Kikinis, "Deformation Analysis for Shape Based Classification," presented at the 17th International Conference on Information Processing in Medical Imaging, 2001.
- [19] T. D. Wager, K. L. Phan, I. Liberzon, and S. F. Taylor, "Valence, gender, and lateralization of functional brain anatomy in emotion: a meta-analysis of findings from neuroimaging," *NeuroImage*, vol. 19, pp. 513-531, 2003.