

# Non-Invasive Determination of Electromechanical Time Intervals of Cardiac Cycle Using Abdominal ECG and Doppler Ultrasound Signals from Fetal Hearts

AH Khandoker<sup>1</sup>, Y Kimura<sup>2</sup>, T Ito<sup>2</sup>, M Palaniswami<sup>1</sup>

<sup>1</sup>The University of Melbourne, Victoria, Australia

<sup>2</sup>Tohoku University, Sendai, Japan

## Abstract

*Fetal ECG and Doppler ultrasound signals provide clinically significant information concerning the physiological state of a fetus. In this study, we propose a non-invasive system to recognize the timings of fetal cardiac events on the basis of analysis of fetal ECG and Doppler ultrasound signal together. Fetal ECG was extracted from transabdominal ECG (10 normal subjects, 38-41 weeks of gestation) using blind source separation with the reference signal. Multiresolution wavelet analysis enabled the frequency contents of the Doppler signals to be linked to the opening and closing of the heart's valves (Aortic and mitral). The time intervals from R peak of fetal ECG to opening and closing of aortic valve were found to be  $99.16 \pm 22.07$  (msec) and  $222.70 \pm 21.83$  (msec) respectively. The time intervals from R peak to opening and closing of mitral valve were found to be  $305.32 \pm 22.71$  (msec) and  $37.84 \pm 18.23$  (msec) respectively.*

## 1. Introduction

Congenital heart defects (CHD) and foetal distress (e.g. low oxygen levels in foetus) are the most common major causes of congenital abnormalities and foetal mortality. The prevalence is 3–8 per 1000 pregnancies at birth [1,2]. Studies have shown that an early detection of some foetuses with potentially ductal-dependent CHD results in an improvement of hemodynamic status, neonatal morbidity and surgical outcome [3]. Foetal distress is associated with postmaturity (when the placenta malfunctions in a post-term pregnancy) or with complications of pregnancy or labour that affect the woman and therefore also affect the foetus. The definition of CHD and foetal distress during foetal life, where the examiner must deal with a patient who cannot be visualized directly and is within another individual, presents unique challenges. At the same time, there has been a growing social demand in developed countries for

an earlier and better prenatal diagnosis, supported by the possibility of choose whether to continue or not with the pregnancy when the foetus is affected by a congenital anomaly.

Long QT syndrome is one of the prevalent CHDs characterized by the presence of a prolonged QT interval on electrocardiography (ECG) and a high risk for developing life-threatening arrhythmias and sudden cardiac death in children and adults [4]. Long QT syndrome has been shown to be an ion channel disorder. This syndrome is considered to be one of the common causes of sudden infant death [5]. There have been two reports describing prenatal cardiotocographic findings in foetuses with long QT syndrome [6-7]. However, to our knowledge, definitive prenatal diagnosis of this congenital syndrome has not been described.

Maternal risk factors and a large number of intrapartum causes lead to foetal hypoxia. Diagnostics of distressed unborn baby is mainly aimed at detection of occurrence of intrauterine hypoxia. Consequences resulting from foetal hypoxia appear in its heart activity [8]. In perinatal medicine, non-invasive cardiotocography (CTG) which is a record of the foetal heart rate (FHR) measured from a transducer on the abdomen is commonly used. However, even with the high specificity, the CTG monitor has the low sensitivity [9]. There is also a method that uses systolic time interval (STI) which can be calculated with an invasively measured foetal electrocardiogram (FECG) via scalp electrodes and a Doppler shift of ultrasound beam reflected from moving valves of foetal heart. Even though it can provide high diagnostic sensitivity, it can not apply until the occurrence of uterine rupture.

A new research paradigm is, therefore, required to address the above mentioned issues with applied research outcomes. Foetal ECG and Doppler ultrasound signals provide clinically significant information concerning the physiological state of a foetus. In this study, For better diagnosing foetus prenatally as having CHD (e.g. long QT syndrome) and foetal distress (e.g. hypoxia), we propose a novel non-invasive system to

recognize the timings of foetal cardiac events on the basis of analysis of electrical (foetal ECG) and mechanical (Doppler ultrasound (DUS) signals) heart activity together.

## 2. Methods

Simultaneous recording of the abdominal ECG signals and Doppler ultrasound signals from ten mothers at the gestational age of 38~41 weeks were collected from Tohoku University Biomedical Engineering Research Organization (TUBERO) database. A total of 10 recordings (10 minutes length) were sampled at 1KHz with 16-bit resolution.

The Doppler ultrasound data were obtained using Ultrasonic Transducer 5700 (fetal monitor 116, Corometrics Medical Systems Inc.) with 1.15 MHz signals. The detailed procedure for experimental set up and tansabdominal ECG data collection has been described in our previous study [11]. FECG traces were extracted from using a method that combines cancellation of the mother's ECG signal and the Blind source separation with reference (BSSR) as described in our earlier study [11]. Briefly, the cancellation of the mother's ECG component was performed by subtracting the linear combination of mutually orthogonal projections of the heart vector. Doppler ultrasound signal was taken as reference signal.

## 3. Results and discussion

### 3.1. DUS and its link with specific cardiac motions and relevant challenges

An example of the extracted FECG signal and corresponding ultrasound signal from the non directional (ND) channel are shown in Fig.1. This clearly demonstrate that the content of DUS signals varies on a beat to beat basis. DUS signals were used to monitor valve movements within fetal heart [10]. From extensive studies of the heart's physiology that have already been performed the prominent cardiac motions that occur can be deduced. These are due to cardiac wall movement and valve movement. Atrial contraction is initiated by the P wave while ventricular contraction is related to R wave activity, hence significant content in the ultrasound signal may be expected at these times. Since both sides of the heart are in synchrony and due to the simultaneous operation of the pulmonic and aortic valves and the tricuspid and mitral (atrioventricular) valves, their

individual activity cannot be expected to appear itself in the ultrasound signal. Fig. 1 shows the relative timings of the heart's valves (Ac, Ao, Mc, Mo) and wall movements (Atc, Vc) in relation to the FECG. Doppler frequency shifts associated with cardiac activity can be visualised. As the transducer-to-foetus orientation changes, the structures returning the largest signal will vary. Therefore, all six timing events (four valve motions and two wall motions) are unlikely to be distinguished in each cardiac cycle. Doppler ultrasound signals vary in time, this being due primarily to variations in the relative orientation of the foetal heart and the ultrasound transducer [10]. Obviously foetal movement will therefore greatly affect the received signal.

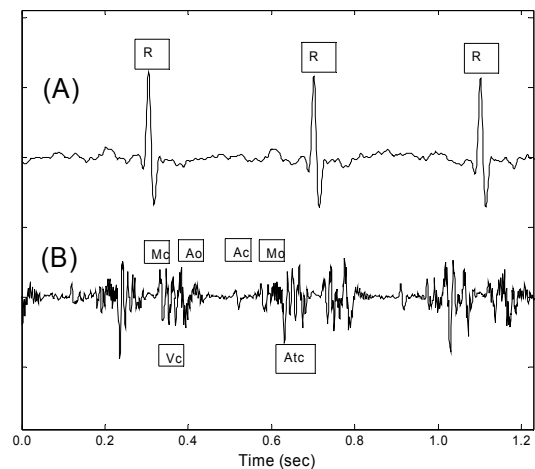


Figure 1. Example of simultaneously recorded fetal ECG and Doppler ultrasound (DUS) data. (A) foetal ECG signal extracted from maternal abdominal signals using Blind source separation with reference (BSSR) [11]. (B) Data from the nondirectional channel of the ultrasound from fetal heart. Annotations showing the timings of the opening and closing of the heart's valves in relation to the electrocardiogram. Mitral (M), Aortic (A) ,opening (o), closing (c); Atc= Atrial wall contraction; Vc= Ventricle wall contraction.

### 3.2. Wavelet analysis of DUS signals

Interpretation of DUS signals in relation to cardiac motions and valve movements would be difficult unless time frequency analysis was not used. Wavelet analysis has become a powerful tool for analysis of nonstationary signals whose spectral characteristics change significantly over time. A discrete wavelet transform uses a set of basis functions to decompose a signal into the detailed signals and the approximate signals of the

original signal. Daubechis wavelet with order 10 was used as mother wavelet in this study.

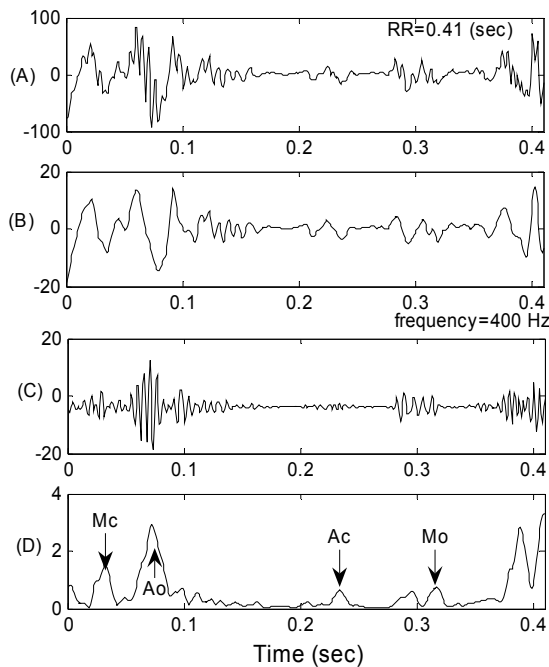


Figure 2. (A) Doppler ultrasound (DUS) signal over a normal R-R interval (0.41 sec). (B) Its approximate signal at level 2. (C) Detailed signal at level 2. (D) Approximate signal at level 2 of the absolute value of the signal in panel C.

Fig. 2 shows an example of the FECG for one cardiac cycle (RR interval=0.41 sec) together with ND channel DUS signals and its approximate and details signals at level 2 wavelet decomposition. The timings of cardiac valve motions with respect to the ECG, the origin of the events highlighted within the DUS were elucidated. In this study cardiac cycles of RR intervals longer than 0.33 second were used for analysis.

In order to detect the peak timings of valve motion events, the time durations within each RR interval chosen for each event were 0.000 ~ 0.06 sec for Mc, 0.06~0.18 sec for Ao, 0.18~0.26 sec for Ac and 0.26~0.33 for Mo.

Fig. 3 shows another example of FECG of longer cardiac cycle (RR interval=0.56 sec). The time interval from R peak to Mo was found to be longer than that in normal cardiac cycle.

Table 1 shows the mean duration of each of the cardiac events (e.g. valves opening and closing timings from R peak of FECG namely R-Ac, R-Ao, R-Mc, R-Mo) within each RR interval. There were cases where all

events could easily be recognized. However, there were also cases where only particular events were observed.

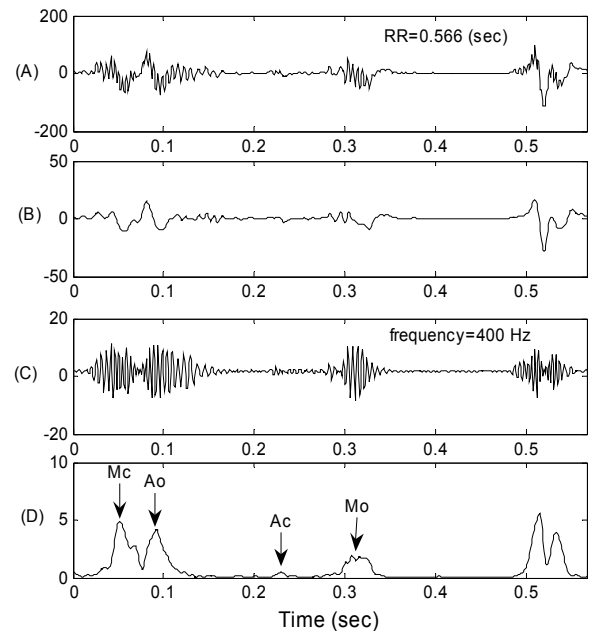


Figure 3. (A) Doppler ultrasound (DUS) signal over a long R-R interval (0.566 sec). (B) Its approximate signal at level 2. (C) Detailed signal at level 2. (D) Approximate signal at level 2 of the absolute value of the signal in panel C.

Table 1: Summary of time intervals of opening and closing of the heart's valves from R peak of FECG over each cardiac cycle. Mean R-R intervals [439.36±49.68 msec (N=1228)].

	R-Mc	R-Ao	R-Ac	R-Mo
Number of RR intv	780	806	1207	1060
Mean (msec)	37.84	99.16	222.70	305.32
Standard deviation	18.23	22.07	21.83	22.71

### 3.3. Relationship of R-Ac and R-Mo with R-R intervals

R-Ac duration did not appear to be significantly influenced by beat to beat variation of R-R interval (Fig. 4), which was in accordance with another study [8],

which reported that Q-Ac duration did not significantly change in heart rate. In contrast to the relationship of R-Ac with R-R,  $R^1\text{-Mo} [= (R-R) - (R\text{-Mo})]$  was found to be strongly affected by the change of R-R interval (Fig. 5).

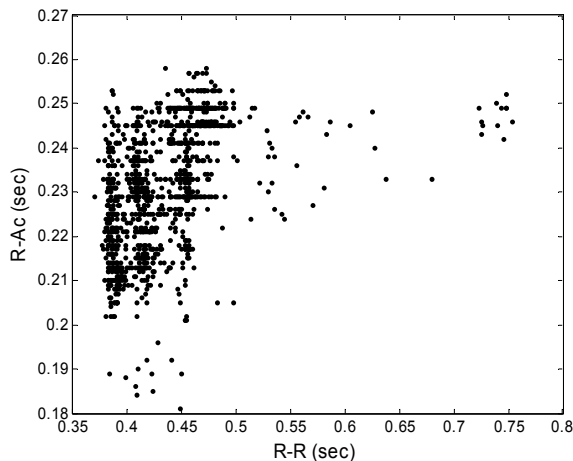


Figure 4. Relationship between R-Ac and R-R intervals in 10 subjects (38-41 weeks of gestation).

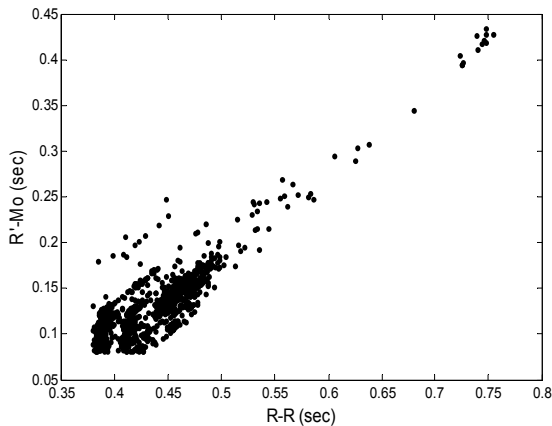


Figure 5. Relationship between  $R^1\text{-Mo}$  and R-R intervals in 10 subjects (38-41 weeks of gestation).

#### 4. Conclusions

Doppler ultrasound data demonstrated with wide variations in the signal content observable on a beat-to-beat basis. Multiresolution wavelet analysis enabled the frequency contents of the Doppler signals to be linked to the opening and closing of the heart's valves (aortic and mitral). These results suggest means by which the cardiac events that contribute to the Doppler signal may be

distinguished, providing information for better recognizing the fetal arrhythmia, anoxia and heart failure.

Further research on modelling of the relationship of cardiac valve timings with R-R intervals over wider range will be attempted on diverse sample size.

#### Acknowledgements

This study was supported by grants from TUBERO, Japan and Australian Research Council Intelligent sensing, sensor networks and information processing research network.

#### References

- [1] Ferencz C, Rubin JD, McCarter RJ. Congenital heart disease: prevalence at live birth. The Baltimore-Washington infant study. *Am J Epidemiol* 1985;121: 31-6
- [2] Hoffman JIE. Incidence of congenital heart disease: I. Postnatal incidence. *Pediatr Cardiol* 1995;106:103-13
- [3] Bonnet D, Coltri A, Butera G, et al. Detection of transposition of the great arteries in fetuses reduces neonatal morbidity and mortality. *Circulation* 1999; 99:916-8
- [4] Schwartz PJ. The long QT syndrome. *Curr Probl Cardiol* 1997;22: 297-351.
- [5] Schwartz PJ, Stramba-Badiale M, Segantini A, Austoni P, Bosi G, Giorgetti R, Grancini F, Marni FD, Perticone F, Rosti D, Salice P. Prolongation of the QT interval and the sudden infant death syndrome. *N Engl J Med*, 1998; 338: 1709-1714.
- [6] Vigliani M. Romano-Ward syndrome diagnosed as moderate fetal bradycardia: a case report. *J Reprod Med*. 1995; 40: 725-728
- [7] Hofbeck M, Ulmer H, Beinder E, Sieber E, Singer H. Prenatal findings in patients with prolonged QT interval in the neonatal period. *Heart*. 1997; 77: 198-204.
- [8] Matonia A, Jezewski J, Kupka T, Wrobel J, Horoba K, Widera M. Instrumentation for Fetal Cardiac Performance Analysis During the Antepartum Period. Proceedings of the IEEE Engineering in Medicine and Biology 27th Annual Conference, NY, 2005; 1-4.
- [9] Charles S, Donnerstein RL. Ultrasonic Assessment of Cardiac Function in the Intact Human Fetus. *Journal of American College of Cardiology* 1985;5:84-94.
- [10] Murata Y and Martin, C. B. Systolic time intervals of the fetal cardiac cycle, *Obstet. Gynecol.*, 1974; 44: 224-232
- [11] Sato M, Kimura Y, Chida S., Ito T, Katayama N, Okamura K., Nakao M. A Novel Extraction Method of Fetal Electrocardiogram From the Composite Abdominal Signal. *IEEE Trans on Biomed Engg.*, 2007; 54 (1): 49-58.

Address for correspondence

Ahsan Khandoker

Dept. of Electrical & Electronic Engg. The University of Melbourne, VIC -3010, Australia.

E-mail: [a.khandoker@ee.unimelb.edu.au](mailto:a.khandoker@ee.unimelb.edu.au)