

Assessment of Osteoarthritis Severity by Wavelet Analysis of the Hip Joint Space Radial Distance Signature

Ioannis Boniatis, Elias Panagiotopoulos, Dimitrios Lymberopoulos, and George Panayiotakis*

Abstract— Osteoarthritis (OA) is a major cause of morbidity worldwide, representing the most common form of arthritis. The radiographic assessment of OA-severity is mainly relied on qualitative criteria, evaluating structural alterations of the joint. In the present study a computer-based image analysis method was developed for the grading of hip OA-severity from radiographic images. The sample of the study comprised 64 hips (18 normal, 46 osteoarthritic), corresponding to 32 unilateral and bilateral hip-OA patients. Two experienced orthopaedists assessed OA-severity from pelvic radiographs, employing the Kellgren and Lawrence (KL) grading scale. Accordingly, 3 KL-based OA-severity categories were formed: (i) “Normal / Doubtful”, (ii) “Mild / Moderate”, and “Severe”. After radiographs digitization their contrast was enhanced by means of the Contrast Limited Adaptive Histogram Equalization method. Employing custom developed algorithms: (i) 64 ROIs, corresponding to patients’ Hip Joint Spaces (HJSs), were determined on the processed radiographs, and (ii) the Radial Distance Signature (RDS) of each HJS-ROI was generated, as the sequence of the Euclidean radial distances between the “centre of mass (centroid)” and each point of the HJS-ROI contour. The generated RDS was subject to the Discrete Wavelet Transform (Coiflet1 wavelet, Level 2 decomposition). Statistical measures of the generated wavelet coefficients were used for the formation of feature vectors, representative of the HJS-ROIs. These vectors were involved in the design of a grading system, based on the Bayes classifier, which was used for the discrimination between: (i) normal and OA hips, and (ii) hips of “Mild / Moderate” and “Severe” OA. The classification accuracy achieved regarding the discrimination between normal and OA hips was 95.3%, while the relevant score for the characterization of hips as of “Mild / Moderate” or “Severe” OA was 91.3%. The proposed system could be of value for the management of hip OA patient.

I. INTRODUCTION

OSTEOARTHRITIS (OA) is a musculoskeletal disorder, associated with significant social consequences and health economic implications [1]. The condition involves all the tissues of the joint, although the loss of articular cartilage as well as alterations in periarticular bone are considered as the most characteristic features of the disease

Manuscript received June 19, 2008.

I. Boniatis and G. Panayiotakis are with the Department of Medical Physics, School of Medicine, University of Patras, 265 00, Patras, Greece (*corresponding author: +30 2610969131; fax: +30 2610996113; e-mail: panayiot@upatras.gr).

D. Lymberopoulos is with the Department of Electrical and Computer Engineering, School of Engineering, University of Patras, 265 00, Patras, Greece.

E. Panagiotopoulos is with the Department of Orthopaedics, School of Medicine, University of Patras, 265 00, Patras, Greece.

[2]. Plain film radiography is accepted as the imaging modality of reference for the assessment of the osteoarthritic joint in daily clinical routine [3]. The typical radiographic features indicating the presence of OA in the hip joint comprise osteophytes, Hip Joint Space (HJS) narrowing, development of subchondral cysts, sclerosis of the subchondral bone, and abnormalities of bone contour [2], [4]. In the context of radiographic assessment of OA, the evaluation of the severity of the disease is mainly based on the use of qualitative grading scales. The latter comprise a number of severity grades, the definition of which relies on aspects of joint structural alterations, visualized on plain radiographs [5]. The Kellgren and Lawrence (KL) grading scale [6] is considered as the gold standard for epidemiological studies of the disease, despite its deficiencies [7].

On the basis of digital image analysis terminology, the shape of an object is a feature of great significance for object description and recognition purposes. Furthermore, shape analysis techniques attempt to provide a descriptive quantitative characterization of shape [8]. Several pathological conditions are associated with alterations concerning the morphology of anatomical organs and regions. Thus, shape analysis of biomedical images may provide quantitative diagnostic information of potential value for the characterization of the depicted anatomical structures [9].

A shape alteration associated with hip OA is the narrowing of radiographic HJS. The particular radiographic finding has been considered as a defining criterion for epidemiologic studies of the disease [10], while the monitoring of HJS-narrowing has been accepted as the most reliable index for the monitoring of OA progression [4]. HJS-narrowing reflects, indirectly, the progressive and non-uniform loss of the articular cartilage due to OA [4], which results in the differentiation of the shape of radiographic HJS in osteoarthritic hips.

Gregory et al. [11] demonstrated the feasibility of a shape analysis approach, based on the concept of Active Shape Models [12], regarding both the quantification of shape alterations of the proximal femur in OA, and the provision of image markers for monitoring of the disease progression. In previous studies performed by our group, the capacity of shape analysis of radiographic HJS for the grading as well as the quantification of hip OA-severity has been documented [13]-[17]. However, all our previous works concerned the utilization of shape analysis approaches, which provided

uniresolution and single-scale spectral shape features of radiographic HJS. The present study aims to extend the already existing approaches concerning the assessment of hip OA severity on the basis of shape information. In this context, the capacity of *multiresolution* shape descriptors of radiographic HJS, regarding the assessment of osteoarthritic alterations of the hip joint is investigated. The generation of these multiresolution shape features was accomplished by the suitable combination of the concepts of wavelet analysis and contour-based shape representation. Previous research works have been reported regarding the recognition of two-dimensional object contours, on the basis of wavelet contour representation algorithms [18], [19]. However, to the best of our knowledge, a relevant approach for the radiographic assessment of hip OA has never been previously reported.

The present study is concerned with the development of a computer-based image analysis system for the grading of hip OA-severity from radiographic images. To this end: (i) the radiographic HJS was represented by its Radial Distance Signature, (ii) the latter was subject to the Discrete Wavelet Transform (DWT) and a number of wavelet coefficients were generated, (iii) a classification scheme, designed on the basis of the generated coefficients, was implemented for the characterization of hip OA-severity.

II. MATERIALS AND METHODS

A. Clinical Sample and Radiographic Images

The sample comprised 64 hips (18 normal, 46 osteoarthritic), corresponding to 32 patients of unilateral (18) and bilateral (14) hip OA. The diagnosis of OA was based on the clinical and radiographic American College of Rheumatology criteria [20]. For each patient a pelvic radiograph was available. All radiographs were obtained following a specific radiographic protocol. The latter concerned use of the same X-ray unit (Siemens, Polydoros 50, Erlangen, Germany), tube voltage 70-80 kVp, 100 cm focus to film distance, alignment of the X-ray beam 2 cm above the pubic symphysis, use of a fast screen and film cassette (30 cm x 40 cm). Radiographs were digitized employing a laser digitizer for medical applications (Lumiscan 75, Lumisys, Sunnyvale, CA, USA) [21], and following a digitization protocol, which comprised image depth of 12 bits (4096 gray levels) and spatial resolution of 146 ppi (5.75 pixels / mm). The radiographic severity of hip OA was assessed by consensus of two experienced orthopaedists, on the basis of the KL grading scale [6]. The latter defines five severity categories via an equal number of grades, ranging between 0 and 4. Grade 0 is assigned to a normal hip joint, while grade 4 indicates a severe osteoarthritic condition. Intermediate levels of OA-severity, characterized as “Doubtful”, “Mild”, and “Moderate” are described by the grades 1, 2, and 3, respectively [6]. For the needs of the present study three major KL-based severity categories were formed: “Normal-Doubtful (KL=0,1)”,

“Mild-Moderate (KL=2, 3)”, and “Severe (KL=4)”. In this context, 18 hips were assigned to the “Normal-Doubtful”, 16 to the “Mild / Moderate”, and 30 to the “Severe” category.

B. Determination of Radiographic Hip Joint Space

On each digitized pelvic radiograph, 2 ROIs, corresponding to patient’s both radiographic HJSs were determined, employing custom developed algorithms in Matlab software (The MathWorks Inc., Natick, USA). The whole procedure concerned the following steps: (i) contrast enhancement and emphasis of the articular margins of the hip joint by implementing the Contrast-Limited Adaptive Histogram Equalization method [22]. (ii) Formation, on the basis of patient’s anatomical landmarks, of an acute angle of 45° , providing the medial and lateral limits of the HJS-ROI [23]. As it can be observed from Fig. 1, the medial limit was defined by the line joining the centre of the femoral head (O, summit of the angle) and the highest point of the homolateral sacral wing (V). On the other hand, the lateral limit was defined by a line (OB), drawn automatically by the program at 45° to the medial limit. The aforementioned anatomical landmarks were selected so as the weight-bearing portion of the femoral head being encompassed within the acute angle, as proposed by Conrozier et al. [23]. The landmarks were marked manually on the digitized radiographs by each of the orthopaedists, using a graphic cursor. (iii) Manual delineation of the inferior and superior articular margins of the joint, corresponding to upper margin of the femoral head and the roof of the acetabulum, respectively.

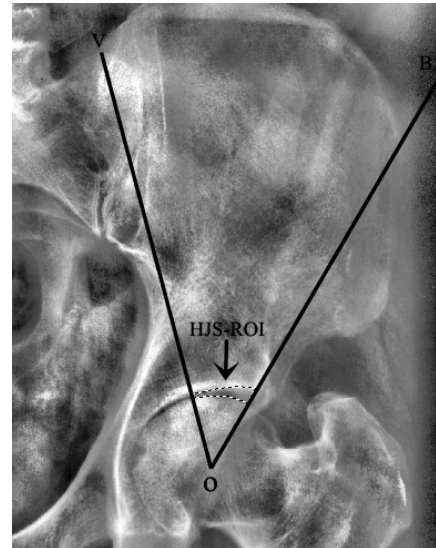


Fig. 1. Determination of the Hip Joint Space (HJS) ROI. VOB: acute angle of 45° . Dotted line represents the delineated articular margins.

The determined HJS-ROI (see Fig. 2a) was further subject to shape analysis.



Fig. 2. Segmented Hip Joint Space Region Of Interest of Fig. 1 (a) and corresponding contour and centroid (*) (b).

C. Generation of Radial Distance Signature

The two-dimensional radiographic depiction of the hip joint contour (see Fig. 2b) was turned into one-dimensional (1-D) by generating the Radial Distance Signature (RDS) [24] of the determined HJS-ROI (see Fig. 4a). For the needs of the present study, the RDS was generated employing custom developed algorithms in Matlab software, according to the following steps:

- (i) Determination of the centre of “mass” (“centroid”) of the HJS-ROI (see Fig. 2b).
- (ii) Tracing of the exterior boundary of the HJS-ROI.
- (iii) Calculation of the radial Euclidean distances between the centroid and each point of the exterior boundary of the HJS-ROI.

In particular, assuming that the exterior boundary of the ROI comprises N pixels, the coordinates of the centroid (x',y') are given by:

$$x' = \frac{1}{N} \sum_{n=1}^N x(n) \quad (1), \text{ and } y' = \frac{1}{N} \sum_{n=1}^N y(n) \quad (2)$$

where $x(n)$ and $y(n)$ are the discrete coordinates of each contour pixel [24]. The HJS-RDS is then defined as:

$$\text{HJS-RDS}(n) = \{[x(n)-x']^2 + [y(n)-y']^2\}^{1/2} \quad (3)$$

Considering the computational approach followed for the generation of the HJS-RDS, the latter, practically, represents a 1-D sequence of radial Euclidean distances, which can also be considered as a 1-D discrete signal.

D. Calculation of multiresolution shape features

The multiresolution shape features of radiographic HJS were calculated within a methodological context concerning the wavelet analysis of the generated HJS-RDS. In particular, employing custom developed algorithms in Matlab software, the HJS-RDS was subject to the Discrete Wavelet Transform (DWT) [25], so as a multiresolution (multilevel) signal decomposition being performed.

The DWT concerns the decomposition of a discrete signal into a hierarchy set of orthogonal approximation and detail signal functions (coefficients). The former represent the high-scale, low frequency components of the analyzed signal, while the latter represent the low-scale, high frequency components. On the basis of digital signal processing terminology the DWT can be considered as a filtering process, employing a proper pair of complementary filters. Within this framework, and considering the case of the single-level wavelet analysis, the decomposition of the signal concerns its convolution with (i) a low pass, and (ii) a high pass filter. The result of the first filtering task is the generation of the approximation coefficients, while the second filtering process leads to the generation of the detail coefficients. The low pass filter involved in the decomposition process is associated with the, so called, scaling function ϕ , while the high pass filter is related with the wavelet function (mother wavelet) ψ . The multiresolution (multilevel) analysis of a discrete signal

concerns the iteration of the previously described decomposition process, with the approximations obtained at each level been further-successively decomposed. The DWT, in contradiction to the Continuous Wavelet Transform, concerns the calculation of wavelet coefficients not for every possible, but for specific subsets of scales and positions of the analyzing wavelet. By selecting dyadic scales and positions (i.e. subsets of scales and positions, based on powers of two) the analysis can be fast, yet accurate and efficient [25], [26]. Thus, the speed, the accuracy and the efficacy of the DWT led us to the utilization of the specific method in the present study.

Compared to Fourier analysis, which permits the evaluation of a signal in the frequency domain exclusively [24], Wavelet analysis renders capable the decomposition of a signal into components localized in both the time (spatial) and the frequency domains [25], [26]. Accordingly, wavelet signatures convey information associated to local spectral features, while Fourier spectral signatures contain solely frequency relevant information. The fact that in wavelet analysis both the frequency and the time (spatial) content of the signal are retained, wavelet signatures can be considered as of enriched information content.

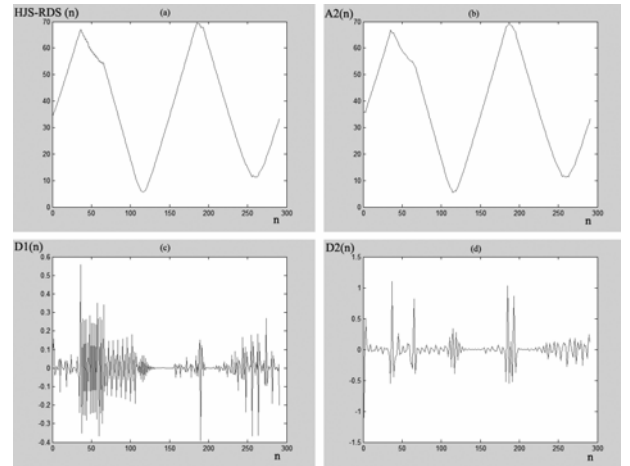


Fig. 4. (a) Radial Distance Signature (RDS) generated for the Hip Joint Space (HJS) Region Of Interest (ROI) of Fig. 2. (b) Approximation RDS signal at Level 2, (c) Detail signal at: Level 1, and (d) Level 2, obtained by Level 2 wavelet decomposition of the RDS signal.

For the needs of the present study, a level 2 decomposition was implemented, employing the Coiflet1 (‘Coif1’) wavelet [26]. Accordingly, three sets of wavelet coefficients were generated, corresponding to the two detail levels as well as the one approximation level (see Fig. 4). For each one of the 3 sets of wavelet coefficients, the following statistical measures were calculated and were utilized as multiresolution shape features: (i) *mean value*, (ii) *median value*, (iii) *maximum value*, (iv) *minimum value*, (v) *range*, (vi) *standard deviation*, (vii) *skewness*, (viii) *kurtosis*, (ix) *mean absolute deviation*, and (x) *median absolute deviation*. In this context, the representation of the HJS-ROI at each decomposition level concerned the formation of a 10-dimensional feature vector, comprising the

mentioned statistical measures of wavelet coefficients. It has to be noted that the selection of the Coif1 wavelet as mother wavelet was performed on a multiple trials basis. In this context, several wavelet functions, available within Matlab, were used for the decomposition of the RDS signal. After multiple trials it was found that the best classification results were accomplished for multiresolution features generated for a Coif1 based multi-scale decomposition.

E. Design of the Computer-Based Grading System

The assessment of hip OA-severity was performed by a computer-based grading scheme, implemented on the basis of the Bayes classifier. The latter was used for the discrimination between: (i) Normal and osteoarthritic hips, and (ii) hips of “Mild / Moderate” and “Severe” OA.

The Bayes classifier implements a statistical pattern recognition approach, based on Bayes formula from probability theory. The classifier is designed so as to minimize the average risk (probability of misclassification) associated with a discrimination task. For a classification problem concerning the assignment of an unknown pattern \mathbf{x} into one of N classes $\omega_1, \omega_2, \dots, \omega_N$, the Bayes classifier decides by utilizing functions of the form:

$$d_k(\mathbf{x}) = \ln P(\omega_k) - (1/2) \cdot \ln |\mathbf{C}_k| - (1/2) \cdot [(\mathbf{x} - \mathbf{m}_k)^T \cdot \mathbf{C}_k^{-1} \cdot (\mathbf{x} - \mathbf{m}_k)]$$

(5) $k=1, 2, \dots, N$, where \mathbf{C}_k and \mathbf{m}_k represent the covariance matrix and the mean vector of class ω_k , respectively, T indicates transposition, $p(\mathbf{x}|\omega_k)$ stands for the class-conditional probability density function, describing the distribution of pattern vectors within the class ω_k , while $P(\omega_k)$ represents the a priori probability concerning the occurrence of class ω_k . The pattern \mathbf{x} is assigned to the class associated with the highest value of the decision function $d_k(\mathbf{x})$ [9].

In order to determine the feature combination providing the highest classification accuracy with the minimum number of features (“optimum” or “best” feature combination) the exhaustive search procedure was followed in conjunction with the Leave One Out (LOO) classification error estimation method. Given the size of the sample which was available for the present study, the task of feature selection, as well as those of classifier training and testing were carried out by not utilizing separate training and test sets. In this context, the LOO method was used so as to estimate the overall accuracy of the categorization scheme. It has to be noted that the specific method is widely employed in pattern recognition studies concerning limited number of available data samples [27]. The LOO approach permits the evaluation of the classification performance on the basis of data samples that are not used for the design of the classifier.

In the present study, features were exhaustively combined each other (i.e. combinations of two, three, etc. features) in order to form a feature vector (exhaustive search). For every feature combination, the classifier was designed employing all the feature vectors (patterns) of the sample, but one. This

pattern was considered as an unknown one and was used in order to determine the committed classification error (LOO). The whole procedure was repeated as many times as the number of the patterns of the sample. In order to safeguard against variations in the dynamic range of the generated features, a fact that could result in inaccurate classification scores, the features were normalized to zero mean and unit standard deviation [9].

F. Statistical Analysis

The Lilliefors test was used in order to assess the normality of distributions for the generated features [28]. The Student’s t-test was used for the investigation of the existence of statistically significant differences between normal and osteoarthritic hips for multiresolution shape features following normal distributions. For non-Gaussian distributions, the existence of significant differences was assessed by means of the Wilcoxon ransksun test [29]. In both cases, the significance level was set at 5%. The Coefficient of Variation (CV) was used in order to evaluate both the intra-observer and the inter-observe reproducibility concerning the determination of HJS-ROIs [29]. Accordingly, each one of the experienced orthopaedists evaluated separately all radiographs twice, with about a month’s interval between evaluations. The obtained scores were utilized for the calculation of the CV. Matlab Statistics Toolbox was used for the statistical analysis.

III. RESULTS AND DISCUSSION

A degenerative alteration in OA is the progressive and non-uniform loss of articular cartilage. In a radiographic image this loss is indicated by the narrowing of HJS, which induces differentiations in the shape of the specific anatomical region. Considering the segmented HJS-ROI as an object within a digital image [30], the shape of the object is expected to determine the position of its centre of “mass” (‘centroid’). Thus, alterations in the shape of HJS, due to narrowing, are expected to differentiate the centroid position. On the other hand, abnormalities of the bone contour of the joint are radiographic findings, which define the disease [2]. The generation of HJS-RDS involves both the centroid of radiographic HJS, and the pixels corresponding to the radiographic depiction of the hip joint contour. Thus, it seems reasonable to assume that the RDS signal is expected to convey diagnostic information, relevant to OA alterations of the hip joint. In the present study, the diagnostic information was associated to the wavelet coefficients corresponding to the detail and approximation components of the RDS, obtained according to the DWT. The latter rendered capable a multi-resolution analysis of the shape signal associated to the articular margins of the hip joint. In this context, the generated multiresolution shape features supplement the already existing ones, which have been documented as of value for the assessment of OA alterations of the hip joint [13]-[17].

Statistical analysis revealed the existence of statistically significant differences ($p < 0.05$) between normal and osteoarthritic hips for the generated multiresolution shape descriptors. The specific finding complies with shape alterations of the osteoarthritic hip joint.

All measurements were found to be reproducible. Regarding the intra-observer and the inter-observer reproducibility of HJS determination, the CV was found equal to 3.2% and 4.0%, on average, indicating the reliability of the determination process. In addition, feature values that were generated from the twice-determined HJS-ROIs did not differ significantly ($p > 0.05$). It has to be noted that in previous studies performed by our group, the region of radiographic HJS had been determined on the basis of manual delineation [13], [15]-[17], [31]-[34] or automatic segmentation [14]. The latter concerned the use of an Active Contours (Snakes) segmentation model [35]. However, and given the reproducibility of the manual determination process, manually determined HJS-ROIs were employed in the present study.

TABLE I
CLASSIFICATION RESULTS FOR THE DISCRIMINATION BETWEEN
NORMAL AND OSTEOARTHROTIC HIPs

Hip	Normal	Osteoarthritic	Accuracy (%)
Normal	17	1	94.4
Osteoarthritic	2	44	95.6
Overall Accuracy			95.3

The highest classification accuracy accomplished regarding the discrimination between normal and osteoarthritic hips was 95.3% (see Table I). In particular, the Bayes classifier discriminated successfully 61 out of 64 hips, employing a four-dimensional (best) feature vector. The latter comprised the statistical measures of *mean value*, *minimum value*, *mean absolute deviation*, and *median absolute deviation*, calculated from the wavelet coefficients corresponding to the second detail decomposition level. The specificity accuracy achieved was 94.4%, given the correct characterization of 17 out of 18 normal hips. Finally, the sensitivity accuracy raised to 95.6%, corresponding to successful discrimination of 44 out of 46 degenerated hips.

Table II tabulates the classification results for the discrimination task concerning the characterization of osteoarthritic hips as of "Mild / Moderate" or "Severe" OA. As it can be observed, the Bayes classifier assigned to the proper categories 42 out of 46 osteoarthritic hips, accomplishing an overall accuracy of 91.3%. Referring to hips of "Mild / Moderate" OA, 3 of them were misclassified, and thus the relevant classification score was 81.2%. On the other hand, only one out of 30 hips of "Severe" OA was incorrectly characterized as of "Mild / Moderate" OA, providing an accuracy of 96.7%. The aforementioned scores

TABLE II
CLASSIFICATION RESULTS FOR THE DISCRIMINATION BETWEEN HIPs
OF MILD / MODERATE AND OF SEVERE OSTEOARTHROTIC

Hip	Mild / Moderate	Severe	Accuracy (%)
Mild / Moderate	13	3	81.2
Severe	1	29	96.7
Overall Accuracy			91.3

were achieved for the optimum feature combination comprising the features *mean value*, *median value*, *maximum value*, and *median absolute deviation*. Again, the second detail level coefficients were used as computational basis of the aforementioned multiresolution shape descriptors.

The multiresolution shape features, calculated as statistical measures of the generated wavelet coefficients, provide information relevant to the energy distribution of the RDS signal, in both the spatial and the frequency domains.

The aforementioned classification scores were accomplished on the basis of the LOO classification error estimation method. However, safer conclusions regarding the performance of the classification system could be drawn by the utilization of distinct training and test sets. Additionally, a more comprehensive representation for the classification performance of the system could be provided by a Receiver Operating Characteristic (ROC) curve.

Several approaches have been proposed for the quantitative assessment of radiographic HJS. In a previous study the discrimination between normal and osteoarthritic hips had been performed by the application of quantitative thresholds on manually measured HJS-width values on colon radiographs, with an error rate of 3.6% for joints with $HJS\text{-width} \leq 2.5$ mm [36]. In previous studies performed by our group textural information extracted from the region of radiographic HJS had been employed in the design of pattern recognition schemes for the discrimination among OA-severity categories. The accomplished classification accuracies were relatively high, justifying the utilization of radiographic texture of HJS as a parameter of potential value for the diagnostic assessment of hip OA (detailed results can be found in Refs. [31]-[34]). In addition to the aforementioned approaches, the shape of radiographic HJS has been employed for the characterization of hip OA in our previous works. As in the case of texture analysis, the implementation of shape-based classification schemes resulted in successful discrimination among various grades of hip OA-severity [13]-[17].

The relatively high classification scores accomplished by the utilization of multiresolution shape features, may indicate the potential value of the suggested approach regarding the assessment of hip OA-severity.

IV. CONCLUSION

The findings of the present study indicate that structural alterations of the hip joint in OA condition can be reliably assessed by multiresolution shape features. The latter provide quantitative diagnostic information on the basis of wavelet coefficients, associated with the radiographic depiction of the articular margins of the hip joint. The utilization of the aforementioned shape descriptors in the design of a classification system resulted in high classification scores, regarding the characterization of hip OA-severity. The suggested approach may contribute to the management of osteoarthritic patients.

ACKNOWLEDGMENT

The authors thank the personnel of the Departments of Radiology and Orthopaedics of the University Hospital of Patras for their contribution to the present work.

REFERENCES

- [1] P. M. Brooks, "Impact of osteoarthritis on individuals and society: how much disability? Social consequences and health economic implications," *Curr. Opin. Rheumatol.*, vol. 14, pp. 573-577, 2002.
- [2] N. Arden and M.C. Nevitt, "Osteoarthritis: epidemiology," *Best Pract. Res. Clin. Rheumatol.*, vol. 20, pp. 3-25, 2006.
- [3] C. Buckland-Wright, "Which radiographic techniques should we use for research and clinical practice?," *Best Pract. Res. Clin. Rheumatol.*, vol. 20, pp. 39-55, 2006.
- [4] R.D. Altman, J.F. Fries, D.A. Bloch, et al., "Radiographic assessment of progression in osteoarthritis," *Arthritis Rheum.*, vol. 30, pp. 1214-1225, 1987.
- [5] Y. Sun, K.P. Günther, and H. Brenner, "Reliability of radiographic grading of osteoarthritis of the hip and knee," *Scand. J. Rheumatol.*, vol. 26, pp. 155-165, 1997.
- [6] J.H. Kellgren and J.S. Lawrence, "Radiological assessment of osteoarthrosis," *Ann. Rheum. Dis.*, vol. 16, pp. 494-501, 1957.
- [7] T.D. Spector and C. Cooper, "Radiographic assessment of osteoarthritis in population studies: wither Kellgren and Lawrence?," *Osteoarthritis and Cartilage*, vol. 1, pp. 203-206, 1993.
- [8] W. K. Pratt, *Digital image processing*. New York: John Wiley & Sons, Inc., 2001, ch. 18.
- [9] S. Theodoridis and K. Koutroumbas, *Pattern recognition*. Amsterdam: Elsevier-Academic Press, 2003, ch. 2, 7, 9.
- [10] P. Croft, C. Cooper, C. Wickham, and D. Coggon, "Defining osteoarthritis of the hip for epidemiologic studies," *Am. J. Epidemiol.*, vol. 132, pp. 514-522, 1990.
- [11] J. S. Gregory, J. H. Waarsing, J. Day, et al., "Early identification of radiographic osteoarthritis of the hip using an Active Shape Model to quantify changes in bone morphometric features. Can hip shape tell us anything about the progression of osteoarthritis?," *Arthritis Rheum.*, vol. 56, pp. 3634-3643, 2007.
- [12] T.F. Cootes, C.J. Taylor, D.H. Cooper, and J. Graham, "Active shape models: their training and application," *Computer Vision and Image Understanding*, vol. 61, pp. 38-59, 1995.
- [13] Boniatis I., Costaridou L., Cavouras D., Kalatzis I., Panagiotopoulos E., and Panayiotakis G., "A morphological index for assessing hip osteoarthritis severity from radiographic images," *Br. J. Radiol.*, vol. 81, pp. 129-136, 2008.
- [14] I. Boniatis, D. Cavouras, L. Costaridou, I. Kalatzis, E. Panagiotopoulos, and G. Panayiotakis, "Computer-aided grading and quantification of hip osteoarthritis severity employing shape descriptors of radiographic Hip Joint Space," *Comput. Biol. Med.*, vol. 37, pp. 1786-1795, 2007.
- [15] I. Boniatis, D. Cavouras, L. Costaridou, I. Kalatzis, E. Panagiotopoulos, and G. Panayiotakis, "A decision support system for the automatic assessment of hip osteoarthritis severity by hip joint space contour spectral analysis," *Lecture Notes in Computer Science (LNCS)*, vol. 4345, pp. 451-462, 2006.
- [16] I. Boniatis, L. Costaridou, D. Cavouras, E. Panagiotopoulos, and G. Panayiotakis, "A morphological descriptors based pattern recognition system for the characterization of hip osteoarthritis severity from x-ray images," *Nucl. Instr. Methods Phys. Res., Sect. A.*, vol. 580, pp. 1093-1096, 2007.
- [17] I. Boniatis, D. Cavouras, L. Costaridou, I. Kalatzis, E. Panagiotopoulos, and G. Panayiotakis, "Radial measures of hip joint space outline for computer aided characterization of osteoarthritis severity," in *Proc. Information Technology Applications in Biomedicine (ITAB) International Special Topic Conference on Information Technology in Biomedicine*, Ioannina, 2006.
- [18] H.S. Yang, S.U. Lee, and K.M. Lee, "Recognition of 2D object contours using starting-point-independent wavelet coefficient matching," *J. Vis. Commun. Image R.*, vol. 9, pp. 171-181, 1998.
- [19] Q.M. Tieng and W.W. Boles, "Recognition of 2D object contours using the wavelet transform zero-crossing representation," *IEEE Trans. Pattern Anal. Mach. Intell.*, vol. 19, pp. 910-916, 1997.
- [20] R. Altman, G. Alarcón, D. Appelrouth, et al., "The American college of rheumatology criteria for the classification and reporting of osteoarthritis of the hip," *Arthritis Rheum.*, vol. 34, pp. 505-514, 1991.
- [21] Lumiscan 75, system specifications. Lumisys Inc. 1998; Available: <http://www.lumisys.com/support/manuals.html>.
- [22] S.M. Pizer, E.O.P. Amburn, J.D. Austin, et al., "Adaptive histogram equalization and its variations," *CVGIP (Computer Vision, Graphics and Image Processing)*, vol. 39, pp. 355-368, 1987.
- [23] T. Conrozier, A.M. Tron, J.C. Balblanc, et al., "Measurement of the hip joint space using automatic digital image analysis," *Rev. Rhum. (Engl. Ed.)*, vol. 60, pp. 105-111, 1993.
- [24] R.M. Rangayyan, *Biomedical image analysis*. Boca Raton: CRC Press LLC, 2005, chs. 2, 6.
- [25] S.G. Mallat, "A theory for multiresolution signal decomposition: the wavelet representation," *IEEE Trans. Pattern Anal. Machine Intell.*, vol. 11, pp. 674-693, 1989.
- [26] I. Daubechies, *Ten lectures on Wavelets*. Philadelphia: CIAM Press, 1992, ch. 8.
- [27] R.M. Haralick, K. Shanmugam, and I. Dinstein, "Textural features for image classification," *IEEE Trans. Syst. Man Cybern.*, vol. SMC-3, pp. 610-621, 1973.
- [28] H.W. Lilliefors, "On the Kolmogorov-Smirnov test for normality with mean and variance unknown," *J. Am. Stat. Assoc.*, vol. 62, pp. 399-402, 1967.
- [29] G. van Belle, L. D. Fisher, P.J. Heagerty, and T. Lumley, *Biostatistics. A methodology for the health sciences*. New Jersey: Wiley-Interscience, 2004, ch. 3.
- [30] R.C. Gonzalez and R.E. Woods, *Digital image processing*. New Jersey: Prentice-Hall Inc., 2002, ch. 11.
- [31] I. Boniatis, L. Costaridou, D. Cavouras, E. Panagiotopoulos, G. Panayiotakis, "Quantitative assessment of hip osteoarthritis based on image texture analysis," *Br. J. Radiol.*, vol. 79, pp. 232-238, 2006.
- [32] I. Boniatis, L. Costaridou, D. Cavouras, E. Panagiotopoulos, and G. Panayiotakis, "A computer-based image analysis method for assessing the severity of hip joint osteoarthritis," *Nucl. Instr. Methods Phys. Res., Sect. A.*, vol. 569, pp. 610-613, 2006.
- [33] I. Boniatis, L. Costaridou, D. Cavouras, I. Kalatzis, E. Panagiotopoulos, and G. Panayiotakis, "Osteoarthritis severity of the hip by computer-aided grading of radiographic images," *Med. Bio. Eng. Comput.*, vol. 44, pp. 793-803, 2006.
- [34] I. Boniatis, L. Costaridou, D. Cavouras, I. Kalatzis, E. Panagiotopoulos, G. Panayiotakis, "Assessing hip osteoarthritis severity utilizing a probabilistic neural network based classification scheme," *Med. Eng. Phys.*, vol. 29, pp. 227-237, 2007.
- [35] C. Xu, J.L. Prince, "Snakes, shapes, and gradient vector flow," *IEEE Trans. Image Process.*, vol. 7, pp. 359-369, 1998.
- [36] T. Ingvarsson, G. Hägglund, H. Lindberg, and L.S. Lohmander, "Assessment of primary hip osteoarthritis: comparison of radiographic methods using colon radiographs," *Ann. Rheum. Dis.*, vol. 59, pp. 650-653, 2000.