

Is “Silent Ischemia” Detectable by Endocardial Pacemaker Leads?

F Palleri¹, I Corazza¹, E Marcelli², L Cercenelli²,
A Branzi¹, R Zannoli¹

¹Cardiovascular Department, University of Bologna, Italy

²Clinical Radiology Dept, Biomedical Technology Unit, University of Bologna, Italy

Abstract

The purpose of the following pilot study is to evaluate the possibility to detect the asymptomatic ischemic episodes which often precede dangerous events by means of endocardial signals. Intracardiac electrograms (IEGMs) have been detected in patients undergoing percutaneous transluminal coronary angioplasty (PTCA), a procedure during which ischemic episodes are induced. For 10 patients IECGs have been examined and compared with the surface 12-lead ECGs, used in current clinical practice to make a diagnosis of ischemia. This work takes part in a project (Body Worn) aimed at planning a prompt aid system for patients at high cardiovascular risk implanted with a pacemaker. In case of abnormalities in the endocardial signals detected by pacemaker leads, the intervention procedure is thought to be activated. However, results from primary data show that a diagnosis of silent ischemia cannot be made on the basis of the only IEGMs.

1. Introduction

In patients at high risk of acute cardiovascular events life threatening conditions such as tachycardia or myocardial infarction are often preceded by silent ischemic episodes. An early detection of silent myocardial ischemia (SMI) may allow a faster medical aid, improving clinical outcomes and preventing many episodes of sudden cardiac death [1].

In current clinical practice there are several modalities in diagnosis of SMI [2]. In particular, Holter monitoring has been shown to be of prognostic value. However, long-term monitoring is not practical and shows a significant number of false positive ST changes [3].

These shortcomings may be overcome using intracardiac electrograms (IEGMs). Nevertheless, the detection of SMI by IEGMs recordings is almost unknown.

The purpose of this preliminary study is the evaluation of the possibility to detect SMI by means of intracardiac electrograms.

To mimic SMI episodes we chose PTCA: during this therapeutic procedure in fact, the inflation of the coronary balloon induces an ischemia of non perfused tissue. This temporary ischemia is always detectable by the surface 12-lead ECG. Furthermore ECG enables to localize and quantify the extension of the ischemic area by the measurement of ST segment deviation.

Therefore, in patients undergoing PTCA, at the same time we collected the surface 12-lead ECG to document ischemia, and IEGMs to examine the possible detection of the ischemic episodes.

This investigation has been carried out within a project (Body Worn) aimed at evaluating the feasibility of a prompt aid system in patients implanted with a pacemaker. The pacemaker leads, placed in the right ventricular apex, should monitor IEGMs and in case of dangerous abnormalities, they are expected to transmit IEGMs to an emergency unit by means of a mobile phone in order to localize the patient with a GPS and to activate the intervention procedure. Life threatening conditions such as tachycardia or myocardial infarction can be easily recognized, nevertheless the prompt detection of parameters that could alert for oncoming worsening conditions would be very useful to prevent an emergency and allowing a more effective medical aid. For this reason the detection of silent ischemia on the basis of intracardiac parameters is particularly interesting.

To evaluate the possibility of using IEGMs as trigger signals for the Body Worn intervention algorithm, we compared the electrocardiograms recorded by endocardial and superficial electrodes in patients undergoing PTCA.

2. Methods

A group of 10 patients with coronary artery disease (CAD) undergoing a PTCA have been enrolled in this preliminary study.

The locations of PTCA included in the study were: left anterior descending (LAD), 1°Diagonal, right coronary artery (RCA). Times of inflations were about 30

seconds.

For every patient a surface 12-lead ECG and 3 intracardiac electrograms were acquired, at baseline and during inflations. In Figure 1 a scheme of the position of intracardiac and superficial leads is shown.

To detect intracardiac signals 2 catheters have been used. The first is a four electrodes catheter for electrophysiology (RESPONSE 6 Fr 5 mm spacing-DAIG) and it has been inserted in the apex of the right ventricle from the femoral vein. This catheter provided a unipolar signal UV from lead 2 (cf. fig.1), referred to a patch put in the left upper chest, and a differential signal DV, detected between leads 2 and 4 (cf. fig.1).

The second is a 6 Fr probing catheter (ZUMA EBU, MEDTRONIC) for angioplasty, which has been used as lead to collect an intracoronaric signal (IC). It was advanced from the femoral artery.

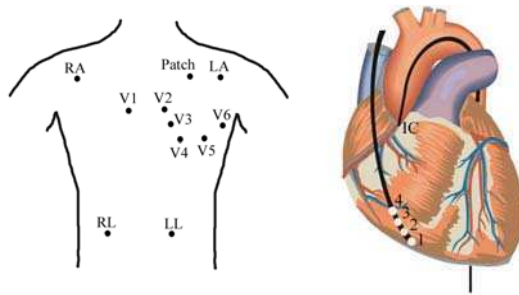


Figure 1: Scheme of the 12 leads of surface ECG and of intracardiac catheters. The quadrupolar catheter is inserted in right ventricle whereas the probing catheter is in the coronary artery.

All the 15 electrocardiograms (12 superficial and 3 intracardiac) have been collected and recorded by the-16 channel-Light Workstation (Spark s.r.l, Bologna).

Signals have been amplified with amplification systems specifically built for this study; a high-pass and a notch filtering were done at 0.05 Hz and 50 Hz respectively. Signals were sampled at 500 Hz and converted with a resolution of 10 bit (range within -2.5 V and 2.5 V). A scheme of the acquisition system is reported in Figure 2.

As regards signal analysis, ST segment deviation, T wave amplitude and QTc have been calculated at baseline (at least 30 seconds before balloon inflation) and during the inflations.

ST segment is a cardinal sign of silent ischemia, and it has been calculated as the difference (in mV) between the value recorded 80 ms after the isoelectric point (J80) and the mean value of PQ interval. The QTc is also an

important parameter for the detection of silent ischemia [4].

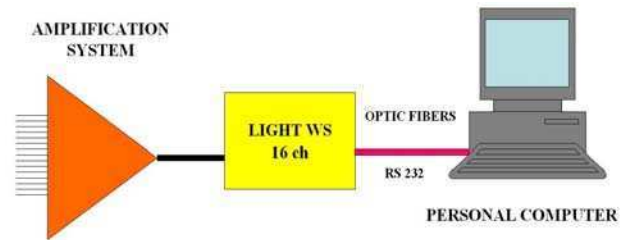


Figure 2: Scheme of the acquisition system: the 15 signals are collected, amplified, A/D converted by a LIGHT Workstation and finally stored in a PC.

3. Results

We acquired a complete set of data for 10 patients, including signals from 15 leads. Electrocardiograms have been recorded at baseline, during balloon inflations and deflations. 3 of 10 patients had multiple lesion types. For each electrocardiogram we calculated ST deviation, T wave amplitude and QTc, at baseline and during each inflation. The number of the overall data was therefore extremely large.

Since patient population had a heterogeneous medical history and signals have been collected for a limited number of patients, data evaluations have been made focusing on each single patient.

The data analysis did not show a clear correlation between external and endocardial parameters during ischemic episodes: ST segment deviation, which is the most important sign of ischemia, is detected by superficial leads in all the considered cases, but it is not always detected by almost one of the intracardiac leads.

Furthermore, the same lesion type treated in two different patients, generated intracardiac signals with different trends.

In Figure 3 a case example of 2 patients treated for the same lesion type (mid-LAD) is shown. The electrograms are detected by DV and UV leads both at baseline and during inflations. It is pointed out how the two signals are significantly different: DV electrogram of patient#1 presents a ST depression whereas UV does not present significant changes during inflations. Patient#2 presents a significant ST elevation in lead UV whereas in lead DV no significant changes are detected.

Moreover, neither the measurement of T wave or QTc relative to endocardial leads gave significant information about the presence of ischemia.

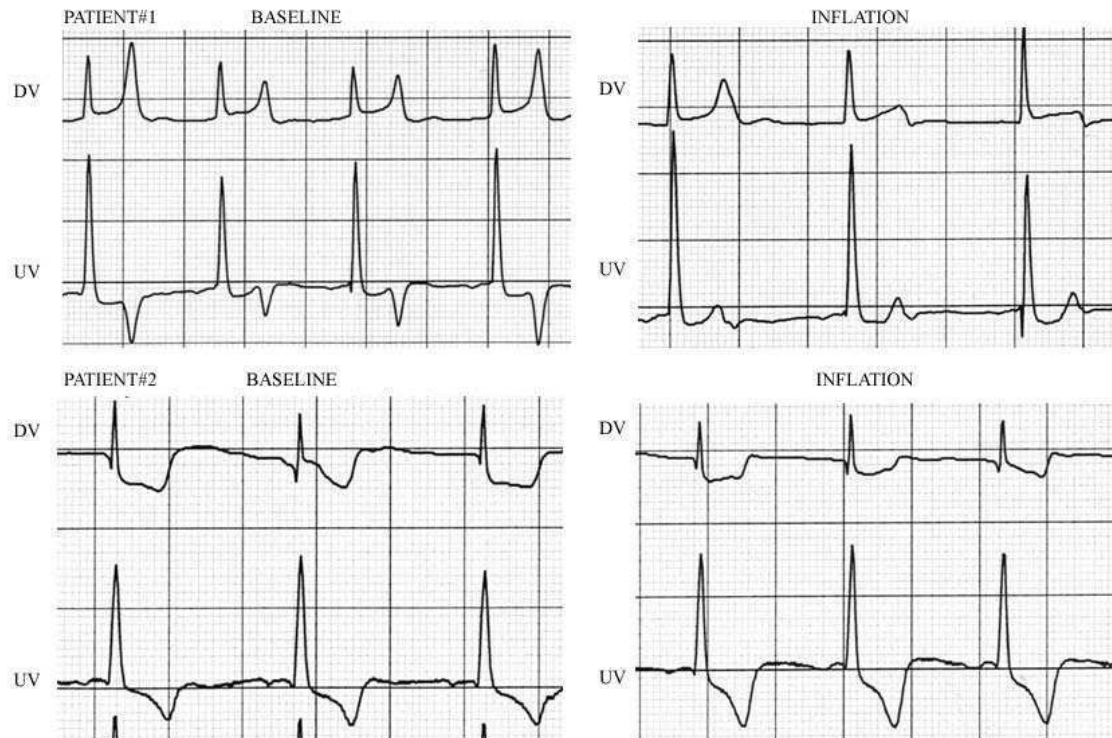


Figure 3: Recordings collected by intracardiac leads DV and UV, at baseline and during an inflation, for two patients with the same lesion type.

4. Discussion and conclusions

In this preliminary study we evaluated the capabilities of IEGMs of detecting SMI. We considered 3 intracardiac signals: one collected by the probing catheter used during PTCA, and the other two collected by leads placed in right ventricle. The last two signals are of great interest because a possible pacemaker useable within the Body Worn project may have leads placed just in right ventricle.

Even if only primary data have been collected, the agreement between superficial and internal signals in the detection of SMI appears poor: the comparisons between superficial and intracardiac signals point out how in some cases internal leads do not detect ischemic episodes which are visible instead in standard surface ECG. Furthermore, for two patients with the same lesion type, intracardiac signals undergo different changes during inflations. In literature there are only a few studies dealing with the detection of SMI by means of

intracardiac leads. They report the ability of IEGMs to detect myocardial ischemia during acute coronary occlusion: IEGMs signals have larger amplitude than ECG signals and ST changes are more visible [5-7].

Nevertheless in our primary data the correlation between internal and superficial signals is not so clear.

The reason may be the time of inflations, that in our investigation were about 30 seconds respect to 60 seconds or more of the quoted studies.

This reduction of time could explain less clearly visible IEGMs.

Furthermore, our primary data refer to only 10 patients enrolled without particular recruitments: a statistically relevant number of patients undergoing PTCA for the same location and with a similar medical history could clarify the correlation between different parameters.

Finally, the detection of SMI on the basis of the only IEGMs is not reliable and for the moment they cannot be used as a trigger for a possible Body Worn intervention. Nevertheless, IEGMs may become an useful tool if associated with the detection of other physiologic parameters. Further studies with a more homogeneous

study population and with a different number and positioning of endocardial electrodes may give a better response.

References

- [1] Cohn PF, Silent myocardial ischemia: Classification, prevalence and prognosis; *Am J Med* 1985;79:2-6.
- [2] Ahmed AH, Shankar KJ, Eftekhari H et al, Silent myocardial ischemia: current perspectives and future directions, *Exp Clin Cardiol* 2007;12:189-196.
- [3] Drew BJ, Wung SF, Adams MG, Pelter MM, Bedside diagnosis of myocardial ischemia with ST-segment monitoring technology: Measurement issues for real-time clinical decision making and trial designs. *J Electrocardiol* 1998; Suppl 30:157-165.
- [4] Michelucci A. et al., Effect of Ischemia Reperfusion on QT Dispersion During Coronary Angioplasty, *PACE* 1996; 19[Pt.II]:1905-1908.
- [5] Bush HS et al., Twelve-lead electrocardiographic evaluation of ischemia during percutaneous transluminal coronary angioplasty and its correlation with reocclusion, *Am Heart J* 1991;121:1591-1599.
- [6] Fischell T.A. et al., Potential of an intracardiac electrogram for the rapid detection of coronary artery occlusion, *Cardiovascular Revascularization Medicine* 2005; 6:14-20.
- [7] Theres H. et al, Comparison of Electrocardiogram and Intrathoracic Electrogram Signals for Detection of Ischemic ST Segment Changes During Normal Sinus and Ventricular Paced Rythms, *Journal of Cardiovascular Electrophysiology* 2002, 13: 990-995.

Address for correspondence:

Francesca Palleri
Cardiovascular Department,
Policlinico S.Orsola-Malpighi
via Massarenti 9,
40138 Bologna ITALY