

# T-Wave Morphology as a Covariate in Drug-Induced QTc Prolongation

C Graff<sup>1</sup>, J Matz<sup>2</sup>, MP Andersen<sup>1</sup>, JK Kanters<sup>3,4</sup>, J Nielsen<sup>5</sup>,  
JQ Xue<sup>6</sup>, E Toft<sup>1</sup>, JJ Struijk<sup>1</sup>

<sup>1</sup>Department of Health Science and Technology, Aalborg University, Aalborg, Denmark

<sup>2</sup>H Lundbeck A/S, Copenhagen, Denmark

<sup>3</sup>Danish National Research Foundation Centre for Cardiac Arrhythmia (DARC), University of Copenhagen, Copenhagen, Denmark

<sup>4</sup>Department of Cardiology P, Gentofte University Hospital, Copenhagen, Denmark

<sup>5</sup>Aalborg Psychiatric Hospital, Aalborg, Denmark

<sup>6</sup>GE Healthcare, Milwaukee, WI, USA

## Abstract

*QT interval prolongation is one of the most common causes of delays and non-approvals in drug development due to the qualitative relationship between this interval and Torsade de Pointes (TdP) arrhythmia. However, not all drugs that prolong the QT interval to the same extent carry the same risk for TdP. Other indications, such as abnormal T-wave morphology, may play a role in differentiating between safe and unsafe drugs.*

*We used moxifloxacin and d,l-sotalol to investigate whether concurrent changes for QTc and T-wave morphology could be used to describe the discrepancy in proarrhythmic risk between the two drugs. Our results provide evidence that these drugs have significantly different morphology-duration profiles at similar QTc prolongations. We propose to investigate whether concurrent assessment of QTc and T-wave morphology has general validity for drug safety evaluation.*

## 1. Introduction

The relationship between the QTc prolonging property of a drug and the development of TdP is a complex one, since the causes of QTc prolongation for a specific drug may or may not be overlapping with the etiology of TdP [1]. In general however, the risk of arrhythmia appears to increase with the extent of QTc prolongation [2]. It is suggested that TdP is: unlikely to appear for drugs that prolong the mean QTc in thorough QT studies by  $\leq 5$  ms, uncertain for drugs that prolong the QTc interval by 10-20 ms and substantially increased above 20 ms prolongation [3]. TdP is a concern in any patient receiving a drug with QTc prolonging potential. However, drugs that prolong the QT interval to the same extent do not always carry the same risk of causing TdP

[4]. This poses an obvious challenge during drug development and in the reassessment of proarrhythmic potential for existing drugs.

Electrocardiographic repolarization indicators other than QTc may contribute importantly to drug safety evaluation as well. Our previous work has shown that T-wave morphology characteristics, such as those seen in Long QT - type 2 syndrome, can be used as sensitive descriptors of repolarization changes induced by various drugs [5-7]. In the present study, these T-wave morphology characteristics were derived and compared for similar QTc prolongations for two drugs: d,l-sotalol and moxifloxacin. The antibiotic drug, moxifloxacin has a favorable cardiovascular safety profile and is recommended as a positive control in thorough QT studies. No clinical study has ever demonstrated an increased risk of serious cardiac events after moxifloxacin (400 mg – PO or IV). The antiarrhythmic drug d,l-sotalol has a less favorable safety profile with a reported incidence of TdP between 1.8% and 4.8% [8, 9].

We investigate whether the discrepancy in proarrhythmic risk between the two drugs is associated with different morphology-QTc profiles.

## 2. Methods

### 2.1. Study population and design

Data from two drug-studies were included for analysis. A first group of sixty-two healthy subjects (38 males) were given placebo on days 1 to 6 and a single 400 mg dose of moxifloxacin on the seventh day. In a different study, a second group of twenty-one subjects (all males) received 0, 160 mg and 320 mg single oral doses of d,l-sotalol, on three consecutive days [10].

All subjects were between 18 to 45 years of age. Healthy status was confirmed by history, physical examination, normal blood pressure and no use of concomitant medication. Informed consent was obtained.

## 2.2. ECG recordings

Standard 12-lead ECGs of 10 s duration were derived from digital Holter for both study groups on the baseline day and at 11 corresponding times (0.5, 1, 2, 3, 4, 5, 6, 8, 10, 12 and 16 h) after subjects were given moxifloxacin or d,l-sotalol.

## 2.3. ECG processing

Each 10 s ECG was used to form a median beat in the recorded leads using MUSE/Interval Editor software (GE Healthcare, Milwaukee, WI). Principal Component Analysis (PCA) was used to compute principal component median beats from the median beats in leads (I, II, V1-V6). The first principal component T-wave was used to calculate a composite measure of repolarization morphology (MCS: Morphology Combination Score). Fiducial point detection and QT measurements (Fridericia corrected, QTcF) were made automatically using the 12SL algorithm (12SL, GE Healthcare, Milwaukee, WI).

## 2.4. T-wave morphology measures

The composite measure of T-wave morphology, based on asymmetry, flatness and notching, was used to identify drug-induced shape changes of the T-wave. These T-wave characteristics have been shown to identify abnormal repolarization in patients with congenital LQT2 [11] and to be more sensitive than QTcF to repolarization changes induced by various drugs, including: sertindole [5], d,l-sotalol [6] and Lu 35-138 (an investigational antipsychotic) [7].

*Notch:*

A curvature signal was obtained from the first and second derivatives of T-waves, equation 1.

$$(Eq. 1) \text{ Curvature} = - \frac{\frac{d^2y}{dx^2}}{(1+(\frac{dy}{dx})^2)^{3/2}}$$

Deflections in curvature were used to indicate the presence or absence of notches on the T-wave. The magnitude of a notch was measured on a unit amplitude T-wave and assigned to 1 of 3 categories as previously suggested [12]: No notch = 0, moderate notch (perceptible bulge) = 0.5 and pronounced notch = 1.0 (distinct protuberance above the apex).

*Asymmetry:*

The difference in slope profiles between the ascending

and descending parts of the T-wave was used as a measure of asymmetry. The slopes at each point of the descending part of the T-wave were compared with the slopes at corresponding points of the ascending segment. Both segments were normalized with the maximum of the derivative within each segment. Asymmetry was defined as the average squared difference ( $d$ ) between the slope segments, equation 2.

$$(Eq. 2) \text{ Asymmetry} \approx \frac{\sum_{n=1}^N d(n)^2}{N}$$

*Flatness:*

Flatness was calculated as a modified version of the standard kurtosis measure which is often used to describe the peakedness of a probability distribution. The T-wave was normalized to unit area and central moments were calculated using equation 3.

$$(Eq. 3) M_k = \left[ \sum_{n=1}^N (n - M_1) ECG(n) \right]^{\frac{1}{k}}, \quad M_1 = \sum_{n=1}^N n ECG(n)$$

The fourth central moment ( $M_4$ ) was normalized with the squared second moment ( $M_2$ ) and subtracted from unity so that increasing values of flatness would reflect increasing flatness of the T-wave, equation 4.

$$(Eq. 4) \text{ Flatness} \approx 1 - \frac{M_4}{M_2^2}$$

*Morphology Combination Score (MCS):*

The three morphology measures were standardized by their relative variances and a linear combination was calculated to yield an overall composite measure of T-wave morphology, equation 5.

$$(Eq. 5) \text{ MCS} = \text{Asymmetry} + \text{Notch} + 1.6 \times \text{Flatness}$$

## 2.5. Covariance analysis

Time-matched changes from baseline were calculated for all subjects ( $\Delta$ QTcF and  $\Delta$ MCS). All values for  $\Delta$ QTcF and the corresponding  $\Delta$ MCS values were distributed into three predefined bins encompassing the following 10 ms ranges of change from baseline: -5 to 5 ms (bin 1), 5 to 15 ms (bin 2) and 15 to 25 ms (bin 3).

$\Delta$ -values were averaged within each bin for moxifloxacin and for both doses of d,l-sotalol. The concurrent drug-induced change for QTcF and MCS was evaluated using bin averages and the bivariate response for moxifloxacin was compared to the response for both doses of d,l-sotalol. Quadratic curves were fitted to bin averages.

### 3. Results

Drug-induced prolongation of the QT interval and changes in T-wave morphology had different temporal characteristics.

Significant drug effects on QTcF were observed two hours after dose for 160 mg d,l-sotalol and one hour after dose for the 320 mg d,l-sotalol.

The MCS measure of T-wave morphology showed significant effects for 160 mg d,l-sotalol one hour before QTcF prolongation was observed at this dose and thirty minutes before QTcF prolongation was observed for the 320 mg dose of d,l-sotalol.

Moxifloxacin-induced QTcF changes reached significance 2 hours after dose. In contrast, to the d,l-sotalol responses, effects on T-wave morphology for moxifloxacin were delayed one hour with respect to QTcF.

The relative magnitudes of moxifloxacin to d,l-sotalol changes were also different for QTcF and T-wave morphology. Peak change of the mean QTcF for moxifloxacin was 27% and 16% of the peak changes for 160 mg and 320 mg doses of d,l-sotalol, table 1. The corresponding moxifloxacin-induced peak change of the mean for MCS was smaller: 14% and 7%, respectively.

Peak changes of the mean	Moxifloxacin		d,l-sotalol	
	400mg		160 mg	320 mg
$\Delta$ QTcF (ms)	9		<b>35</b>	<b>58</b>
95% CI	7 to 12		26 to 44	48 to 68
$\Delta$ MCS	0.07		<b>0.51</b>	<b>1.07</b>
95% CI	0.02 to 0.12		0.37 to 0.64	0.88 to 1.26

Table 1. Peak changes for time matched means. Bold values indicate a significant difference ( $p < 0.001$ ) between d,l-sotalol and moxifloxacin.

There were steeper relationships between QT interval prolongation and T-wave morphology change for both doses of d,l-sotalol compared to the same relationship for moxifloxacin.

Quadratic regression lines (Fig. 1) were derived from the data. Quadratic regression provided far better estimates for  $\Delta$ MCS versus  $\Delta$ QTcF beyond 20 ms in the case of d,l-sotalol, as compared to linear regression lines, indicating that a linear model would be incorrect.

There were no significant differences between the means for  $\Delta$ QTcF in each of the bins 1-3 in figure 1. Yet, drug-induced changes in T-wave morphology were significantly greater for subjects who received d,l-sotalol compared with subjects who received moxifloxacin, despite comparable QTcF prolongations. Also, the

difference in T-wave morphology changes between the moxifloxacin group and the d,l-sotalol group increased with increasing prolongation of the QT interval.

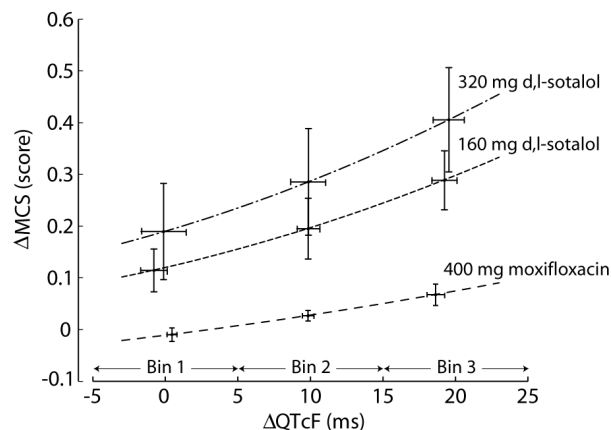


Figure 1. Non-linear relationship between drug-induced QT interval prolongation and T-wave morphology change. I-bars indicate means and 95% confidence intervals. The change in T-wave morphology for a given QTcF prolongation appears to be drug and dose specific.

Noticeably, the moxifloxacin group had T-wave morphology changes for bin 3 ( $\Delta$ QTcF = 15 to 25 ms) that were smaller than those for the 160 and 320 mg d,l-sotalol groups in the lower bin 1 ( $\Delta$ QTcF = -5 to 5 ms):  $\Delta$ MCS<sub>400mg,Bin3</sub> = 0.067 versus  $\Delta$ MCS<sub>160mg,Bin1</sub> = 0.11 and  $\Delta$ MCS<sub>320mg,Bin1</sub> = 0.19, ( $p = 0.02$  and  $p < 0.01$ ).

### 4. Discussion and conclusions

The difference in proarrhythmic risk between moxifloxacin and d,l-sotalol was associated with different T-wave morphology-duration profiles. These findings could have important implications for cardiac safety evaluation in future drug studies.

Currently, the ICH E14 guideline defines a negative thorough QT study as one in which the upper 95% CI for the maximum time-matched mean effect of the drug as compared to placebo is less than 10 ms [3]. However, this conservative threshold was not chosen based on scientific evidence of increased torsadogenic risk for such level of QTc prolongation. This may be rather problematic since it is widely recognized that QTc prolongation is not the core of the problem with drugs causing arrhythmias. In addition, a fixed threshold for safety concern also appears problematic given the evidence that drugs with similar effects on QTc may have very different safety profiles. The likelihood that a safe and effective drug is incorrectly characterized as having torsadogenic potential is therefore real. The implications for sponsors, of such an inappropriate conclusion from a thorough QT trial may

be discontinued development of a new compound or inappropriate restrictive labeling. Conversely, an unsafe drug may reach the market and pose a public health hazard.

Provided that concurrent analysis of QTc and T-wave morphology has general validity for distinguishing between safe and unsafe drugs, this type of multivariate analysis could serve as a supplementary description of drug effects in thorough QT trials. Certainly, improved characterization of repolarization is needed due to the lack of a clear correlation between QTc and cardiac risk.

We propose to further investigate, whether concurrent assessment of QTcF and MCS has general validity for drug safety evaluation

We believe that computerized measures of T-wave morphology would be an important addition to QT interval measurements because such measures may contribute to an expanded ECG safety evaluation in future drug studies through more careful characterization of repolarization abnormalities.

## Acknowledgements

The authors thank H. Lundbeck A/S for providing moxifloxacin data and Pfizer Inc. for providing d,l-sotalol data.

## References

- [1] Antzelevitch C. Arrhythmogenic Mechanisms of QT Prolonging Drugs: Is QT Prolongation Really the Problem? *J Electrocardiol.* 2004;37(suppl.):15-24.
- [2] Roden DM. Drug-Induced Prolongation of the QT Interval. *N Engl J Med.* 2004;350:1013-1022.
- [3] Guidance for Industry: E14 Clinical Evaluation of QT/QTc Interval Prolongation and Proarrhythmic Potential for Non-antiarrhythmic Drugs. October 2005. <http://www.fda.gov/downloads/RegulatoryInformation/Guidances/ucm129357.pdf>. Accessed September 3, 2009.
- [4] Shah RR. Drug-induced Prolongation of the QT Interval: Regulatory Dilemmas and Implications for Approval and Labelling of a New Chemical Entity. *Fundam Clin Pharmacol.* 2002;16:147-156.
- [5] Nielsen J, Graff C, Hardahl T, et al. Sertindole Causes Distinct Electrocardiographic T-wave Morphology Changes. *Eur Neuropsychopharmacol.* 2009;19:702-707.
- [6] Graff C, Andersen MP, Xue JQ, et al. Identifying Drug-induced Repolarization Abnormalities from Distinct ECG Patterns in Congenital Long QT Syndrome: A Study of Sotalol Effects on T-wave Morphology. *Drug Safety.* 2009;32:599-611.
- [7] Graff C, Matz J, Christensen EB, et al. Quantitative Analysis of T-wave Morphology Increases Confidence in Drug-induced Cardiac Repolarization Abnormalities: Evidence from the Investigational IKr Inhibitor Lu 35-138. *J Clin Pharmacol.* 2009 (In press).
- [8] Haverkamp W, Martinez-Rubio A, Hief C, et al. Efficacy and Safety of d,l-sotalol in Patients with Ventricular Tachycardia and in Survivors of Cardiac Arrest. *J AM Coll Cardiol.* 1997;30:487-495.
- [9] Hohnloser SH. Proarrhythmia with Class III Antiarrhythmic Drugs: Types, Risks and Management. *Am J Cardiol.* 1997;80:82G-89G.
- [10] Sarapa N, Morganroth J, Couderc JP, et al. Electrocardiographic Identification of Drug-induced QT Prolongation: Assessment by Different Recording Methods. *Ann Noninvasive Electrocardiol.* 2004;9:48-57.
- [11] Andersen MP, Xue JQ, Graff C, et al. A Robust Method for Quantification of IKr Related T-wave Morphology Abnormalities. *Comput Cardiol.* 2007;34:341-344.
- [12] Lupoglazoff JM, Denjoy I, Berthet M, et al. Notched T Waves on Holter Recordings Enhance Detection of Patients with LQT2 (HERG) Mutations. *Circulation.* 2001;103:1095-1101.

Address for correspondence:

Claus Graff

Department of Health Science and Technology

Aalborg University

Fredrik Bajers Vej 7 E1-209

9220 Aalborg, Denmark

E-mail address: cgraff@hst.aau.dk