

# Data Fusion of Left Ventricle Electro-Anatomic Mapping and Multislice Computerized Tomography for Cardiac Resynchronisation Therapy Optimization

F Tavard<sup>1,2</sup>, A Simon<sup>1,2</sup>, C Leclercq<sup>1,2,3</sup>, P Mabo<sup>1,2,3</sup>, A Hernandez<sup>1,2</sup>, M Garreau<sup>1,2</sup>

<sup>1</sup>INSERM, U642, Rennes, F-35000, France

<sup>2</sup>Université de Rennes 1, LTSI, Rennes, F-35000, France

<sup>3</sup>CHU Rennes, Service de cardiologie et maladies vasculaires, Rennes, F-35000, France

## Abstract

*Cardiac Resynchronization Therapy is a treatment for bi-ventricular asynchronism. It can be optimized by the identification of the most effective pacing sites. The aim of this study is to provide a helpful tool to perform this identification by the fusion of electrical and anatomical information resulting from Electro-Anatomic Mapping (EAM) data and Multislice Computerized Tomography (MSCT) imaging. EAM data provide an approximation of the left ventricle (LV) 3D-surface ( $S_{EAM}$ ). Left cardiac chambers are segmented from MSCT imaging and surfaces are reconstructed ( $S_{CT}$ ). In order to represent this information in a unified framework, a three steps method is proposed: (1) the LV is separated from the left auricle on  $S_{CT}$  providing  $S'_{CT}$ ; (2) a semi-automatic rigid registration method is applied to  $S_{EAM}$  and  $S'_{CT}$ ; (3) activation time delays are estimated on  $S'_{CT}$  from the EAM data. This method results in a graphical interface offering to clinicians means to identify abnormal electrical activity sites.*

## 1. Introduction

Nowadays, Cardiac Resynchronization Therapy (CRT) is accepted as a therapeutic option in heart failure patients who remain highly symptomatic despite optimized medical treatment [1]. However, one third of the patients do not respond to the therapy. The IMOP project (IMaging for Optimisation of biventricular Pacing) aims for CRT optimization using anatomical, mechanical and electrical data which are acquired in pre, per and post-intervention. Two complementary ways lead to the CRT biventricular optimization: the identification of the most effective pacing sites and the search for a transvenous path to access the pacing sites. The pacing sites are myocardium regions with abnormal mechanical or electrical activity. Clinicians therefore need a representation of the myocardium com-

binning electrical and anatomical informations. Our goal is to achieve it by combining Electro-Anatomic Mapping data and Multislice Computerized Tomography imaging.

The fusion of informations is one of the most challenging task in cardiac imaging to improve diagnosis and therapy. Indeed, informations provided by cardiac modalities are very different in terms of resolution (spatial and temporal) or nature (anatomical, mechanical or electrical). On one hand, the data obtained by EAM include: (i) a 3D surface reconstruction from points located inside the LV chamber, (ii) anatomical landmarks and (iii) points where the electrical activity has been measured. On the other hand, MSCT gives the opportunity to precisely represent the Left Ventricle (LV), the myocardium and also the coronary venous network (which is significant in the search of the transvenous path).

The proposed method for the fusion of EAM and MSCT data relies on three steps: (1) from MSCT data: cardiac left chambers segmentation and left ventricle separation from other geometrical structures; (2) spatial 3D surface registration in order to get the two modalities in the same spatial referential; (3) combined electrical and anatomical data representation to give an adapted tool to clinical routine.

3D-registration methods can be divided into two groups: methods based on geometric image features and methods based on voxel similarity measures [2]. EAM provides sparse data, therefore the first set of methods will be considered. The Iterative Closest Point (ICP) [3] is the most popular algorithm for a rigid matching of two 3D surfaces. The ICP algorithm inspired other methods for rigid [4] or non-rigid [5] 3D surfaces registration. In this work a rigid registration method is developed.

Several works have been proposed for the multimodal fusion of cardiac data including EAM [6–8]. They all first apply a rigid Landmark Registration considering either external landmarks (fixed during the clinical routine) or landmarks manually fixed during data processing. The

considered EAM data included geometrical specificities (anatomical structures or external landmarks). Therefore taking into account these informations would assure the registration accuracy. However routine EAM does not necessarily provide these structures thus the proposed semi-automatic registration method does not rely on landmarks of any kind.

We present in this paper a detailed description of the data (EAM and MSCT), the registration and fusion methods before results and discussion.

## 2. Data acquisition and proposed method

### 2.1. Data acquisition

#### 2.1.1. Multislice Computerized Tomography data

The MSCT database was acquired with a Multi-Slice Computerized Tomography scanner (*General Electric Healthcare* LightSpeed VCT 64-slice Scanner) providing reconstructed volumes by ECG post-synchronization. The segmentation of the left endocardium is realized using a fuzzy connectedness algorithm [9, 10]. Using marching cubes [11], a 3D surface (referred as  $S_{CT}$ ) containing the LV, but also the left auricle (LA) and the beginning of the aorta is reconstructed.

#### 2.1.2. Electro-anatomic mapping

EAM is used by clinicians for measuring electrical activities in real time in the cardiac chamber. In this study, the EnSite System (Endocardial Solutions, St. Jude Medical, Inc.) is used. The data acquisition is divided into three stages:

*Anatomical landmarks.* Anatomical landmarks like the apex and the aorta are spotted. These landmarks provide some spatial reference points which help clinicians but are not reliable for exact positions.

*3D Model.* The probe runs through the LV and from its position (localized by three steady magnetic fields), a 3D surface of the chamber (3D Model) is reconstructed. We will refer to this surface as  $S_{EAM}$ .

*Activation time delays mapping.* A probe is placed in the LV, localized using the 3D Model. For every measurement point, the probe records the electrical activity. A peak on the signal denotes the beginning of the electrical activation. The *activation time delays* are then defined by the difference between the instants of the peaks detected on the measurement and on a reference signal (e.g. ECG or local electrical activity in the auricle). Let  $P_{EAM}$  be the set of the  $n$  measurement points of the EAM,  $\delta_i$  the delay value of  $p_i \in P_{EAM}$  with  $i = 1, \dots, n$ . The representation in 3D space of measured times provides the *activation time*

*delays mapping* (figure 1). Several maps are available, depending on the stimulation applied to the myocardium (LV, Right Ventricle, biventricular stimulation or none) during the acquisition process.

## 2.2. Method

In this paragraph the method used for the EAM data and  $S_{CT}$  surface fusion is detailed. The first step is the automatic research of the long axis and the apex on both surfaces and the cut off of the LV from undesired geometric structures on  $S_{CT}$  providing  $S'_{CT}$ . Then,  $S'_{CT}$  and  $S_{EAM}$  surfaces are registered. Finally,  $S'_{CT}$  is used to map the activation time delays from the EAM.

#### 2.2.1. Apex, long axis definition and LV extraction from $S_{CT}$

In order to register both surfaces, the apex and the long axis are searched for on both surfaces.

*Automatic selection of the apex.* For each surface  $S_X$  (where  $X$  is either  $CT$  or  $EAM$ ), an algorithm returns the couple of points  $(M, M')$  separated by the largest Euclidean distance. One of those points is supposed to be the apex. On the EAM, one of the anatomic landmarks given by the clinician localize the apical region. Therefore, on  $S_{EAM}$  the point  $M$  or  $M'$  which is the nearest to this landmark is considered as the apex. During the MSCT acquisition process, the  $Z$ -axis is oriented from the head of the patient to his feet, thus for  $S_{CT}$  we consider as the apex the point of  $(M, M')$  with the greatest  $Z$  value.




Figure 1. EAM surface and EAM measurement points representation. Activation time delays in *ms*.

*Automatic estimation of the long axis.* Once the apex is determined for  $S_X$ , we choose the centroid of  $S_X$  as the second point defining and orienting the long axis.

*Left ventricle extraction.* The input mesh  $S_{CT}$  is the result of the segmentation and surface reconstruction applied to the MSCT images. However the segmentation method extracts not only the LV but also the left auricle and the beginning of the aorta. Since EAM data represent only the LV, the extraction of the LV from  $S_{CT}$  is necessary. It is based on the search of the mitral plane and its use to cut the input mesh. A plane, normal to the long axis and at a distance  $h$  from the apex is used to slice the mesh, providing a closed 2D-contour which area is computed ( $A(h)$ ). The

mitral valve narrowing is resulting in a distinct local minimum of  $A(h)$  (around 52% of maximum height on figure 2). After smoothing this function (mean value on a moving window), the local minimum following the first maximum, starting from the apex is taken as the value of  $h$  defining the mitral plane. Figure 2 illustrates the LV extraction process. As the LV is extracted (giving  $S'_{CT}$ ), the long axis is refined by the apex and the centroid of  $S'_{CT}$ .

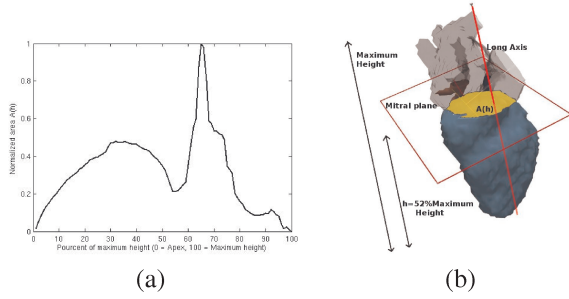


Figure 2. LV extraction by calculating  $A(h)$  and defining the mitral plane. (a)  $A(h)$  starting from the apex ( $h = 0$ ) to maximum height ( $h = 100$ ). (b) Definition of the mitral plane.

### 2.2.2. Surface registration

The proposed method described here considers *a priori* knowledge on the heart geometry. First  $S_{EAM}$  is registered on  $S'_{CT}$  using the location of the apex and the LV long axis, giving  $S'_{EAM}$ . Then we apply a rotation to  $S'_{EAM}$  around the long axis.

In order to evaluate the rotation value  $\hat{\theta}$  (see figure 3) an interface allowing the user to choose  $\hat{\theta}$  by a 3D-visualization of the registration process was developed (figure 4 (a) and (b)). Clinicians are able to visually localize the aorta on  $S_{EAM}$ . Hence  $\hat{\theta}$  can be selected manually according to this interface.

### 2.2.3. Projection of electrical data

The purpose of the fusion step is to represent the activation time delays on  $S'_{CT}$ . For each point of  $S'_{CT}$ , the activation time delay has to be estimated. As represented on figure 1, activation time delays maps are not continuous. Thus the following process is chosen to project the activation time delays on  $S'_{CT}$ .

For  $M_{CT} \in S'_{CT}$ , let us:

1. Centre an open ball  $B$  of radius  $r$  given by the needed precision:

$$N \in B \Leftrightarrow \|\overrightarrow{M_{CT}N}\| < r$$

2. Determine the measurement points of the EAM contained in the open ball:  $E = P_{EAM} \cap B$ .

For  $N_i \in E$ , let  $\delta_i$  be its activation time delay and let  $\alpha_i = \frac{1}{\|\overrightarrow{M_{CT}N_i}\|}$ .

3. Calculate  $\Delta(M_{CT})$  the estimated value of the activation time delay:

$$\Delta(M_{CT}) = \frac{\sum_{N_i \in E} \alpha_i \delta_i}{\sum_{N_i \in E} \alpha_i} \quad (1)$$

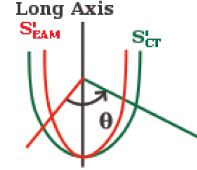


Figure 3. Rotation of  $S'_{EAM}$  around the long axis by an angle  $\theta$ .

## 3. Results and discussion

We applied these registration and fusion methods to databases provided by the IMOP project. Indeed, several patients have been selected in this clinical protocole on whom EAM and MSCT acquisitions have been realized. The different steps of the proposed method are illustrated on figure 4.

We opt for representing the activation time delays map on the MSCT-surface. Our Graphical User Interface (GUI) shows the two surfaces after the registration of apex and long axis. The final step of the registration process is realized by using a value slider to choose the rotation angle to apply to  $S'_{EAM}$  and visualize the result of the transformation.

The GUI allows the user to interact with the surfaces in 3D, choose between the different stimulation types (LV, biventricular, sinusal...) and display the corresponding map. Figures 4 (c), (d), (e) and (f) show the resulting 3D maps for two different stimulations (LV and sinusal) and for two patients. The color map goes from red for smallest values of delay, to blue for greatest values. Consequently, the regions that have early electrical activity are red-colored. For instance, considering LV stimulation (figures 4 (c) and (e)), we have a red (early activation) region on the antero-septal wall and considering the opposite wall (lateral wall), the color turns blue (late activation).

## 4. Conclusion

A registration method and 3D anatomical and electrical maps have been introduced and applied to the left ventricle in EAM and MSCT imaging. A semi-automatic registration method for two reconstructed 3D surfaces from EAM and MSCT imaging as well as an automatic method

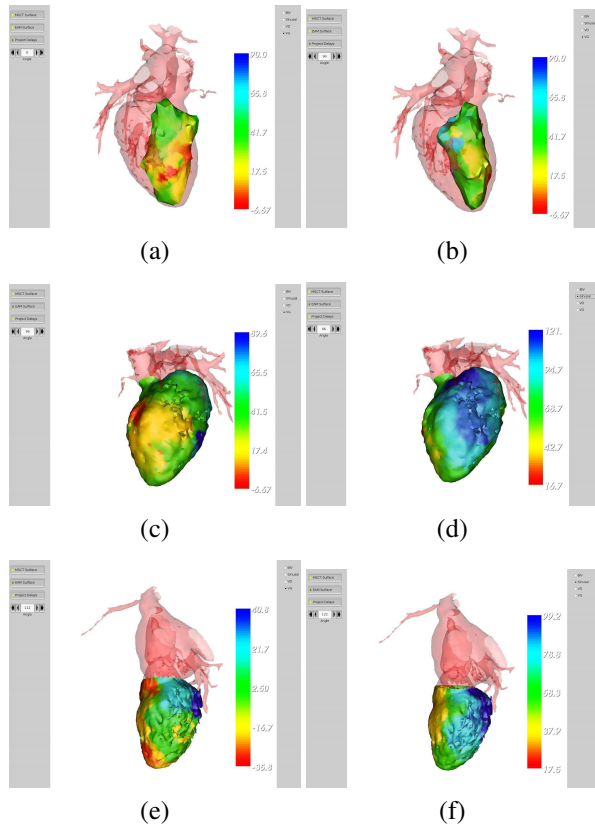


Figure 4. Results of the fusion of activation time delays on the CT-surface for two different patients. First patient: (a) Initial position before rotation. (b)  $S'_{EAM}$  and  $S'_{CT}$  after interactively choosing  $\hat{\theta}$ . EAM activation time delays mapped on  $S'_{CT}$  after LV extraction: (c) for LV stimulation, (d) for sinus stimulation. (e) and (f) same as (c) and (d) for the second patient. Activation time delays in color (*ms*).

to extract the LV from the MSCT reconstructed surface were developed. It provides the clinician with 3D anatomical and electrical maps with the anatomical precision of MSCT imaging. For CRT optimization, the localization of the most delayed sites is possible, providing powerful means for a better detection and localization of pacing sites.

Further works will aim to apply automatic registration method to other EAM data, to combine other modalities from the same patients (MRI for instance), to take into account mechanical considerations, and also to incorporate the venous coronary network.

## Acknowledgements

This work, part of the IMOP research project n° 04 T 187-188-189-190 CITH, is supported by the French Research Ministry.

## References

- [1] Chung ES, Leon AR, Tavazzi L, Sun J, Nihoyannopoulos P, Merlino J, Abraham WT, Ghio S, Leclercq C, Bax JJ, Yu C, Gorcsan J, Sutton MSJ, Sutter JD, Murillo J. Results of the predictors of response to CRT (PROSPECT) trial. *Circulation* 2008;117:2608–2616.
- [2] Mäkelä T, Clarysse P, Sipil O, Pauna N, Pham QC, Katila T, Magnin IE. A review of cardiac image registration methods. *IEEE Transactions on Medical Imaging* 2002;21(9):1011–1021.
- [3] Besl P, McKay ND. A method for registration of 3D shapes. *IEEE Trans Pattern Analysis and Machine Intelligence* 1992;14:239–256.
- [4] Du S, Zheng N, Ying S, You Q, Wu Y. An extension of the ICP algorithm considering scale factor. *IEEE International Conference on Image Processing* 2007;5:193–196.
- [5] Bâty X, Cavarro-Ménard C, Roullier V, Jeune JL. Model based and iconic multimodal registration to merge gated cardiac PET, CT and MR sequences. *EMBS 29th Annual International Conference of the IEEE* 2007;.
- [6] Dong J, Calkins H, Solomon SB, Lai S, Dalal D, Lardo AC, Brem E, Preiss A, Berger RD, Halperin H, Dickfield T. Integrated electroanatomic mapping with three-dimensional computed tomography images for real-time guided ablations. *Circulation* 2006;113 (2):186–195.
- [7] Reddy V, Malchano Z, Holmvang G, Schmidt E, d'Avila A, Houghtaling C, Chan R. Integration of cardiac magnetic resonance imaging with three-dimensional electroanatomic mapping to guide left ventricular catheter manipulation feasibility in a porcine model of healed myocardial infarction. *Journal of the American College of Cardiology* 2004; 44:2202–2213.
- [8] Mäkelä T, Pham Q, Clarysse P, Lotjonen J, Sipil O, Hanninen H, Lauerma K, Knutti J, Katila T, Magnin I. A 3D model-based registration approach for the PET, MR and MCG cardiac data fusion. *Medical Image Analysis* 2003; 7:377–389.
- [9] Udupa J, Samarasekera S. Fuzzy connectedness and object definition : Theory, algorithms, and applications in image segmentation. *Graphical Models and Image Processing* 1996;58(3):246–261.
- [10] Fleureau J, Garreau M, Simon A, Hachemani R, Boulmier D. Assessment of global cardiac function in MSCT imaging using fuzzy connectedness segmentation. In *Computers In Cardiology*. 725-8, 2008; .
- [11] Lorensen WE, Cline HE. Marching cubes: A high resolution 3d surface construction algorithm. *SIGGRAPH Computer Graph* 1987;21(4):163–169. ISSN 0097-8930.

Address for correspondence:

François Tavard  
 LTSI / Université de Rennes 1  
 Bât. 22 Campus Beaulieu, Rennes, F-35000, France  
 +33 2 23 23 62 21  
 francois.tavard@univ-rennes1.fr