

Cardiac Function Estimation Using Multislice Computed Tomography: A Comparison to Speckle Tracking Imaging

A Simon^{1,2}, R Delaunay^{1,2,3}, C Leclercq^{1,2,3}, E Donal^{1,2,3}, M Garreau^{1,2}

¹INSERM, U642, Rennes, F-35000, France

²Université de Rennes 1, LTSI, Rennes, F-35000, France

³CHU Rennes, Service de cardiologie et maladies vasculaires, Rennes, F-35000, France

Abstract

The goal of this work is to evaluate the capabilities of Multislice Computed Tomography (MSCT) to assess local cardiac function. MSCT dynamic acquisition provides datasets representing the whole cardiac cycle, enabling to describe the left ventricle both anatomically and functionally. In order to estimate the cardiac function, a motion estimation method has been proposed, based on a multi-resolution surface matching. It provides the means to compute functional parameters and to display them using compact representation modes. In order to evaluate the estimated displacements, a comparison to US Speckle Tracking Imaging (STI) has been carried out. Results are presented for two patients, using apical 4- and 2-chambers long-axis views, and short-axis views. They highlight a similitude in transverse and radial displacements. A qualitative evaluation shows how MSCT is powerful, providing the means to characterize the local cardiac function in 3D.

1. Introduction

Multislice Computed Tomography (MSCT), combining ultra-fast rotating gantries, multi-rows detectors and retrospective ECG-gated reconstruction, provides datasets representing the whole cardiac cycle with a high spatial resolution. It enables to have in prospect an anatomical description of the cardiac system (ventricles and coronary vessels) but also a functional description (cardiac motion in three dimensions), both obtained in one single examination.

The estimation of the cardiac function has to help for the diagnosis and therapy planning of pathological situations such as atherosclerosis (related to hypokinesia) or asynchronism. Indeed, such a description would be a great mean to improve Cardiac Resynchronization Therapy (CRT). Actually, if CRT is accepted as a therapeutic option in heart failure patients who remain highly symp-

tomatic despite optimized medical treatment [1], one third of the patients do not respond to the therapy [2]. The major ways to improve CRT remain both the identification of the most effective pacing sites and the left ventricular lead positioning.

This work is part of the IMOP project (IMaging for Optimisation of biventricular Pacing) which purpose is to define a CRT optimization method based on the fusion of mechanical, electrical and anatomical data. Our objective is to better plan the placement of CRT leads using the Multislice-CT (MSCT) capabilities in imaging the heart. With this modality, transvenous path finding methods [3] and motion estimation approaches have been previously proposed [4,5]. The goal of this work is to compare the displacements extracted from MSCT data to those obtained with US Speckle Tracking Imaging in order to discuss the capabilities of MSCT to assess local cardiac function.

This paper is organized as follows: first, the cardiac motion estimation method that we have proposed and applied to MSCT imaging is resumed. Speckle Tracking Imaging is then introduced. The method of comparison is then described. Results obtained on two patients databases are presented and discussed in a qualitative way, and followed by some conclusions.

2. Methods

2.1. Cardiac motion estimation in multislice computed tomography

The method we have previously proposed [4,5] for cardiac function estimation relies on three steps: (i) segmentation of the left endocardium along the whole temporal sequence; (ii) reconstruction of the surface meshes corresponding to the segmented surfaces; (iii) temporal surface matching to estimate the displacements of the mesh nodes.

The segmentation process is based on a fuzzy connectedness algorithm. The comparison of computed left ventricular volume to clinical measurements (with MSCT and

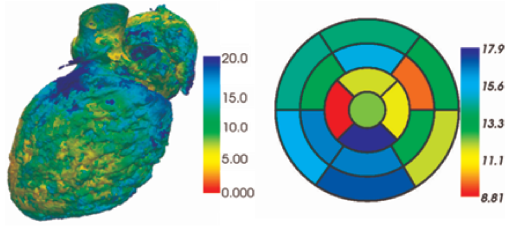


Figure 1. Two representation modes of the cardiac function: maximal displacement (mm) represented in color with a 3D surface (left oblique anterior view) (left) and with a classic bull-eye representation (right).

MRI), such as the comparison of the segmentation with an expert segmentation of reference, have provided satisfying results [6]. The segmented surfaces are then reconstructed using the Marching Cubes algorithm.

The motion estimation relies on the multi-resolution matching of each pair of surfaces (S_1 , S_2) corresponding to two following moments. It is based on the definition of a Markov Random Field F , whose sites are the nodes of S_1 and labels are the nodes of S_2 . The most probable realization of F , according to a global energy U , leads to the estimated motion field. The matching is guided by mean and Gaussian curvatures. In order to take advantage of the spatiotemporal regularity of the motion field, the energy U includes terms privileging low amplitude and spatially regular displacements. A multi-resolution scheme is used in order to optimize the minimization process. At the lowest resolution, the energy minimization is performed using a simulated annealing algorithm while, at higher resolutions, an iterated conditional mode (ICM) algorithm is used.

The application of this method to each pair of successive surfaces S_1 and S_2 results to one motion field associated to each instant of the cardiac cycle and defined on the set of nodes of the corresponding endocardial mesh.

From the obtained motion fields, motion descriptors can be extracted. For instance, maximal displacement (according to the first time-instant of the sequence), time-instant corresponding to this maximal displacement and total displacement can be computed and displayed using different representation modes (e.g. 3D endocardial surface, bull-eye representation based on the 17 cardiac anatomical segments (cf. Fig. 1)).

2.2. Cardiac motion estimation using 2D speckle tracking

Speckle tracking is an image processing method that enables to assess cardiac motion from 2D dynamic echocardiographic images [7]. Routine B-mode grayscale images are analyzed for frame-by-frame movement of stable patterns of natural acoustic markers, or speckles, present in

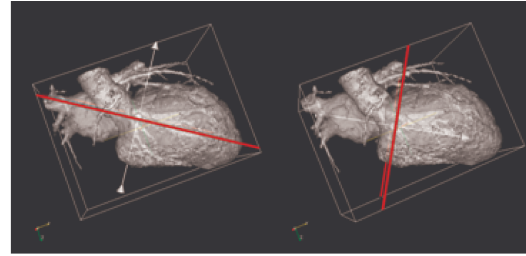


Figure 2. Selection of the echographic plane in the CT data (apical 4-chambers long axis plane (left) and short axis plane (right)).

ultrasound tissue images over the cardiac cycle. The tracking relies on the manual selection of the endocardium contour. It is then extended to consider the whole myocardium and decomposed in segments (about 60 in long-axis view, 40 in short-axis view). Speckle tracking enables to track these segments and therefore to estimate cardiac motion.

The extracted motion is then decomposed, for each segment, in different components used in clinical routine, i.e. transverse and longitudinal components in long-axis view and radial component in short-axis view. Finally, a baseline correction is applied to each motion component in order to correct global displacement caused by patient breathing or probe displacement.

2.3. Comparison of the extracted motions

Because MSCT and STI provide motion descriptors with different characteristics (3D vs. 2D, different spatial and temporal resolutions), a multimodal registration stage is required. It is based on four steps:

- Selection of the echographic plane in the CT data and extraction of the associated motion;
- Temporal interpolation of the extracted CT motion;
- Spatial registration of the CT and US contours;
- Association, to each US data point, of the corresponding CT point.

These four steps are described in the following paragraphs.

Selection of the echographic plane in the CT data. The selection of the plane associated to the echographic acquisition in the CT data is realized interactively. It relies on the selection of three points on the first reconstructed endocardial surface. Once the plane has been selected, it is used to cut through the reconstructed surface to generate a contour corresponding to the echographic plane (cf. fig. 2). For each point of this contour, the neighboring nodes (with a distance lower than 1.5mm) in the original surface mesh are selected and their displacements are averaged. Finally, displacements are decomposed according to the echographic plane.

Temporal interpolation of the extracted CT motion. In order to obtain the same temporal resolution in CT and US

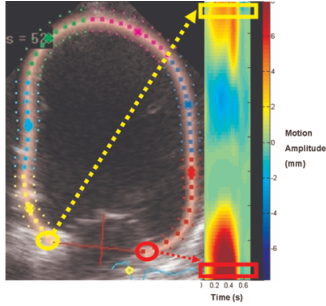


Figure 3. Representation mode used to display motion components.

data, a cubic spline interpolation is applied to each motion component and for each point of the CT contour. Similarly to US data, a baseline correction is applied to the interpolated data.

Spatial registration of CT and US contours. A rigid registration process is used to align CT and US extracted contours. Firstly, an ICP (Iterative Closest Point) algorithm associating rotation and translation is applied to the CT contour. Because the spatial resolution of CT is higher than US resolution, a scaling factor is applied (initialized at 1 and iteratively decreased until the sum of the squared Euclidean distances between closest points stops decreasing). Finally, a second ICP is applied to refine the alignment. Association between CT and US data points. Because the CT spatial resolution is higher than the US one, each US data point is associated to several CT data points. Therefore, for each US data point, the nearest CT data points are selected and their motion components averaged.

After these four steps, one set of points is obtained (corresponding to the US data points) and, for each point, motion components estimated from CT and US data.

In order to display these motion components in a common way, we used a classic US representation (Fig. 3). It is based on the path followed from the base of the septal wall to the base of the lateral wall. For each point, the amplitude of the motion component is displayed according to time. It results to spatiotemporal maps used by physicians to detect intraventricular delays.

3. Results

For two patients, CT data acquisition has been realised with a 64-slices General Electric Lightspeed VCT 64 (GE, Milwaukee, WI, USA), providing 20 3D data volumes (resolution: $0.3 \times 0.3 \times 0.5$ mm) representing a whole cardiac cycle. Transthoracic echocardiography has been performed using a GE Vivid 7 system. Two acquisitions have been realised in apical (long axis) view (4 and 2-chambers views) and three in parasternal short-axis views (basal left ventricle (LV), mid-LV and apical-LV). The frame rate is

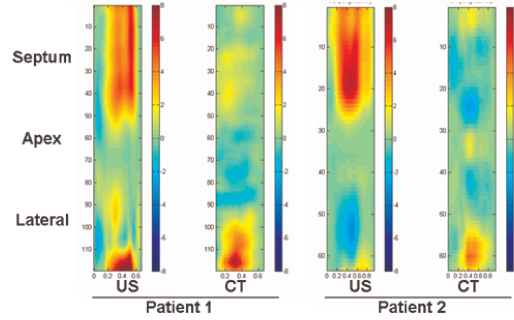


Figure 4. Longitudinal displacements from apical 4-chambers view (patients 1 and 2).

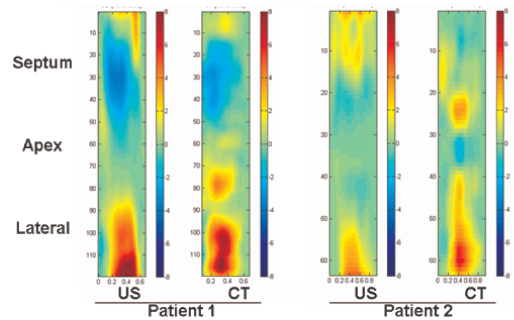


Figure 5. Transverse displacements from apical 4-chambers view (patients 1 and 2).

greater than 65 fr/s. Measurements of myocardial displacements were performed offline in the longitudinal, transverse and radial axes, using a dedicated software package (GE Echopac).

Motion estimated from long axis data is illustrated by figures 4, 5 and 6. Figures 4 and 5 represent, respectively, longitudinal and transverse displacements estimated from 4-chambers acquisitions of the two patients. Figure 6 shows longitudinal and transverse displacements from 2-chambers acquisition of the first patient. The figure 4 shows that longitudinal components significantly differ between CT and US, especially in the septal segments. This is explained by the well-known aperture phenomenon, highlighting a more difficult estimation of motion components parallel to the considered surface, which is the case of the longitudinal motion in the basal and medial segments of the left ventricle.

For transverse displacements (Fig. 5), results are better, especially in the septal and lateral segments. However, transverse motion estimated in the apical segment show important differences. This can be explained by another well-known problem: the difficulty to visualize the apical area in echography. In the segments with good displacements coherence, a temporal delay appears: CT data seems to have an advance of about 100 ms. It is caused by the dif-

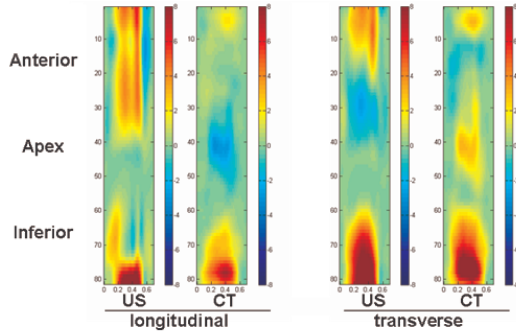


Figure 6. Longitudinal and transverse displacements from apical 2-chambers view, from the anterior to the inferior walls (patient 1).

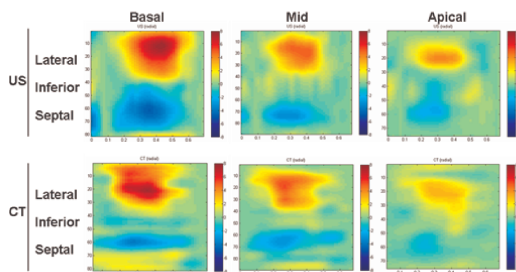


Figure 7. Radial motion from short-axis view (patient 1).

ference in the mode of ECG synchronization: US acquisition starts at the beginning of the QRS complex, while CT acquisition is synchronized on the QRS peak. This results to a temporal difference of about 50 to 100 ms that can be noticed on the spatiotemporal maps.

Results obtained on 2-chambers acquisition (Fig. 6) confirm those obtained on 4-chambers data: longitudinal motion shows very important differences in the anterior segments while transverse displacements highlight an important coherence, excepted in the apical segment. The figure 7 represents radial component in short axis view. The coherence of the estimation of this component is good, even if the delay previously exposed remains.

4. Discussion and conclusions

Assessing local cardiac function with Multislice Computed Tomography would be a great advance towards the anatomical and functional description of the cardiac system within one single examination. In this paper, we propose to compare local motion descriptors estimated with MSCT imaging to those obtained with US Speckle Tracking Imaging. In order to follow clinical routine, displacements are decomposed in different components before being compared.

Results vary greatly according to the represented motion component: transverse and radial displacements show

an important coherence while longitudinal displacements differ significantly.

The coherence shown in transverse and especially radial components is very satisfying because it has been proved that radial component study is the most useful motion component for dyssynchrony characterization [8].

Therefore, this study shows very promising results for the characterization of local cardiac function from MSCT imaging. Moreover, new MSCT generation will provide data with better temporal resolution allowing more precise motion estimation.

Future works will deal with the search for 3D dyssynchrony descriptors from MSCT and on the fusion of these descriptors with venous and myocardial anatomical information.

Acknowledgements

This work is supported by the French Research Minister (n 04 T 187 - 188 - 189 - 190 CITH).

References

- [1] Leclercq C, Kass DA. Re-timing the failing heart: principles and current clinical status of cardiac resynchronization. *J.Am.Coll.Cardiol* 2002;39:194-201.
- [2] Mehra MR, Greenberg BH. Cardiac resynchronization therapy: caveat medicus!. *J.Am.Coll.Cardiol*. 2004;43:1145-1148.
- [3] Coatrieux JL, Hernandez AI, Mabo P, Garreau M, Haigron P. Transvenous path finding in cardiac resynchronization therapy. In *Proc. of the FIMH Conference*. 2005; 236-45.
- [4] Garreau M, Simon A, Boulmier D, Coatrieux, JL, Le Breton H. Surface and motion extraction in cardiac MSCT imaging for the assessment of left ventricular function. *International Journal of Biomedical Imaging* 2006; Article ID 37607.
- [5] Simon A, Garreau M, Boulmier D, Coatrieux JL, Le Breton H. Cardiac Motion Extraction Using 3D Surface Matching in Multislice Computed Tomography. In *Proc. of the MICCAI Conference*. 2004; 1057-59.
- [6] Fleureau J, Garreau M, Simon A, Hachemani R, Boulmier, D. Assessment of global cardiac function in MSCT imaging using fuzzy connectedness segmentation. In *Computers in Cardiology*. 2008; 725-28.
- [7] Langeland S, et al. Comparison of time-domain displacement estimators for two-dimensional RF tracking. *Ultrasound Med Biol* 2003;29(8):1177-86.
- [8] Suffoletto MS, et al. Novel speckle-tracking radial strain from routine black-and-white echocardiographic images to quantify dyssynchrony and predict response to cardiac resynchronization therapy. *Circulation* 2006;113(7):960-8.

Address for correspondence:

Antoine SIMON

LTSI, Campus de Beaulieu, Université de Rennes 1, 263 Avenue du General Leclerc - CS 74205 - 35042 Rennes Cedex, France
antoine.simon@univ-rennes1.fr