

Phantom Limb Pain Treated by Far Infrared Ray

Chi-Yu Huang, Rong-Sen Yang, Te-Son Kuo, and Kai-Hsiung Hsu

Abstract—We have treated a patient with severe phantom limb pain by a novel far infrared ray (FIR) therapy. The patient has suffered persistent and progressively worsening phantom limb pain after amputation ten years ago. He also experienced severe muscle spasm and twitch of stump during the attacks. His phantom limb pain was excruciating and was rated up to 9 by the Visual Analog Pain Scale. Various pain treatment modalities have been used but in vain, including medications and rehabilitation. He also underwent two episodes of sympathectomy, only achieving short-term effects for three months. Then he underwent our new treatment method. We applied FIR to the amputated limb site instead of the stump of the patient for 40 minutes for each treatment session twice a week. One month after the FIR treatment, he felt much improved and rated his phantom pain at 4, and down to 2–3 after two months of treatment. The duration of each phantom limb pain attack has significantly reduced from over 24 hours to only a few minutes or seconds after five months of FIR treatment. During a six-month post-treatment follow-up, his phantom limb pain occurred seldom for only a few seconds at a low 1-2 rating on the pain scale. The analgesic effect of FIR treatment has prevented him from the scheduled third sympathectomy and the risk of heart attack followed by severe twitch of stump. The results of this study demonstrate an easy, non-invasive and effective treatment modality for phantom limb pain.

I. INTRODUCTION

The pain felt in the missing limb is usually referred to as phantom limb pain, occurring commonly in 80-90% of all amputees [1], [2]. To date, most of treatments for phantom limb pain are not effective [3]-[5]. At the end of the 20th century, it is estimated that more than 500,000 Americans still suffer from phantom limb pain [6].

Phantom limb pain is mainly assumed to be related to the disorder of the central or peripheral neurons [7]-[12] while psychological factors are also suggested [13], [14]. Studies have shown that the phantom limb pain is associated with maladaptive plastic changes along the neuraxis [15], [16].

Manuscript received April 23, 2009. This work has been approved by the 133rd meeting of Research Ethics Committee of the National Taiwan University Hospital. The clinical trial registration number is NTUH-REC No.200710042R.

Chi-Yu Huang is with the Department of Electrical Engineering, Biomedical Group, National Taiwan University, Taipei, 10617 Taiwan (e-mail: chiyuhuang@ntu.edu.tw).

Rong-Sen Yang is with the Department of Orthopaedics, College of Medicine, National Taiwan University, Taipei, 10002 Taiwan (e-mail: rsyang@ntuh.gov.tw).

Te-Son Kuo is with the Department of Electrical Engineering and Institute of Biomedical Engineering, National Taiwan University, Taipei, 10617 Taiwan (e-mail: kuo@ntu.edu.tw).

Kai-Hsiung Hsu is with the Department of Biomechatronic Engineering, National Ilan University, I-Lan 26047, Taiwan (corresponding author: phone: 886-3933-3889; fax: 886-3933-3996 e-mail: khhsu@niu.edu.tw).

This change develops in the form of cortical reorganization at the areas of the somatosensory and motor regions [17], [18]. It was further hypothesized that cortical reorganization was caused by the efferent motor cortical activity without afferent sensory feedback [19]. However, the occurrence of cortical reorganization is mainly among upper limb amputees rather than amputees with non-painful phantom sensations [11], [15]. It is also unclear why the cortical representation of the face or lips into the hand area could cause pain sensation instead of an abnormal perception [15], [20].

For hundred of years, amputees have been vividly identifying the amputated limb site as the origin of the limb pain sensations. They even called others to rub their “phantom limb” at the missing limb site to reduce their pain [21]. Phantom limb pain could also be exacerbated or alleviated by external condition such as the weather [3]. Up till now, the effect of applying physical interventions to the phantom limb pain site has not been investigated yet. This study was designed to test the analgesic effect of applying FIR to the phantom limb pain site as well as to investigate the link between phantom limb pain and phantom limb site.

II. METHODS

A. Case description

In September, 1998, a 64-year-old man underwent above-knee amputation due to chondrosarcoma involving his left tibia. The patient has been suffering phantom limb pain since the surgery. Most of his pain occurred as throbbing in phantom toes or heel while lasted for hours or days. Such pain regularly spread from the phantom toes to ankle and up to the stump, followed by severe twitch of stump and muscle spasm, and even a heart attack. This man’s phantom limb pain was excruciating and was rated up to 9 on the Visual Analog Pain Scale. Medication treatments have been used for past nine years but in vain, including nonsteroidal anti-inflammatory drugs-NSAIDs, morphine and Tramadol HCl. Physical interventions and rehabilitation were also adopted but unsuccessfully, including applying massage, infrared ray and warm hydrotherapy to stump as well as planned walking in prosthesis.

As the severe phantom limb pain attacked more frequently and seriously in the recent two years, he underwent first sympathectomy in February, 2007, with the pain relieved only for three months. Then he underwent second sympathectomy in June, 2007. Three months after the second operation, recurrent phantom pain occurred and the third sympathectomy was expected in October, 2007. In the meantime, with the

pharmacological treatment, rehabilitation and sympathectomy failed to relieve his pain, the patient started to take our novel treatment by applying far infrared ray (FIR) to his phantom limb site in November, 2007.

B. New clinical intervention

We applied FIR specifically to the phantom limb pain site (not the stump) specified by the amputee for 40 minutes for each treatment session twice a week. A far-infrared instrument (TY-101N, WS Far IR Medical Tech. Co. Ltd.) with peak energy at the wavelength of $8\ \mu\text{m}$ was used as the FIR source (Fig. 1). The power density of the FIR is $20\ \text{mW}/\text{cm}^2$ at 20 cm away. We used an opaque curtain to preclude psychological interference and an insulator box to isolate the FIR emitter from the patient (Fig. 2). The temperature and FIR power were measured using a thermometer and a FIR power meter at locations around the patient to confirm such isolation.

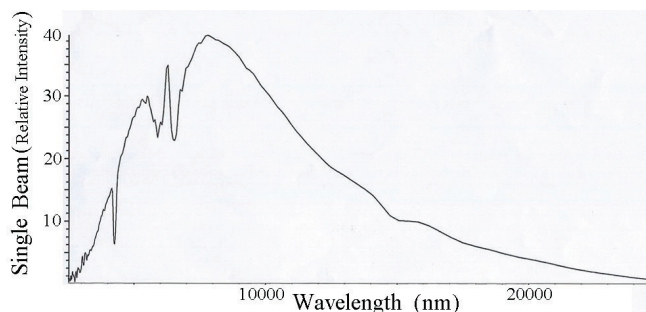


Fig. 1. Spectrum of the far infrared ray for this study

III. RESULTS

A. Pain relief

With the FIR treatment applied, the patient felt much improved and rated his phantom pain score from 9 before the treatment down to 4 after on month of treatment, and down to 2–3 after two months of treatment. The duration of each phantom limb pain attack has significantly reduced from over 24 hours to only a few minutes or seconds after five months of FIR treatment (Fig. 3). Then he stopped the treatment. During a six-month post-treatment follow-up, his phantom pain almost disappeared and occurred occasionally for only a few seconds with a low pain rating of 1–2.

B. Physiological & unusual responses

Without direct contact with the patient’s body during FIR radiation, various physiological responses were still observed from the amputee. During the first week of treatment, the patient had much flatus more frequently than usual, especially for the day of the FIR treatment. The occurrence of passing gas decreased as the patient acquired more FIR treatments and returned to normal after one month of treatment.

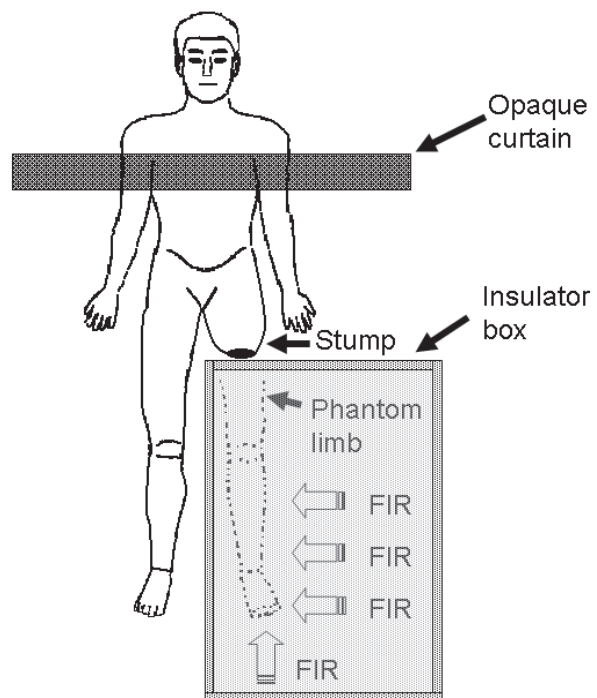


Fig. 2. The FIR treatment setup. An opaque curtain was set between the patient’s upper part and the FIR instrument, and FIR was applied to the “phantom limb pain sites” specified by the amputee. An insulator box was used to isolate the FIR emitter from the stump and the rest of the body, while a thermometer and a FIR power meter (not shown here) were used to confirm such isolation.

During the FIR exposure, the patient reported that he could sense a little warmth at the missing limb site occasionally. Also, his phantom limb was getting “softer” and “relaxed”, opposed to constantly numb and paralyzed prior to the FIR exposure, and he described that his missing leg “came back” again. The more FIR treatments he received, the more relaxed and comfortable sensations his missing limb was. He could even “move” his phantom limb after two months of treatment, and perform sophisticated control like “rotate” the phantom ankle after three months of treatment.

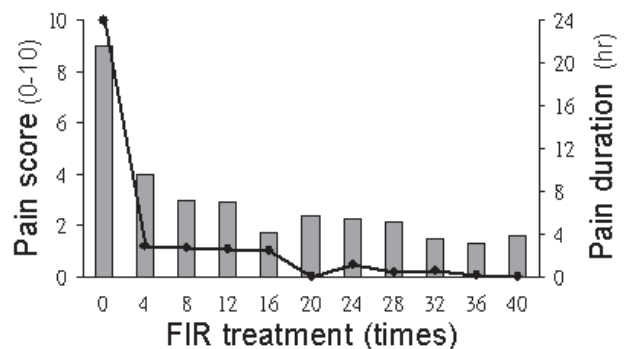


Fig. 3. Bar charts show the average phantom pain intensity and dots indicate the average daily phantom pain duration before (at 0) and after FIR treatments.

IV. DISCUSSION

Our findings showed that the novel FIR therapy reduced phantom limb pain, and the patient had physiological responses to this intervention, including passing gases as well as warm and unusual sensations induced by applying FIR to the absent limb site, indicating the link between phantom limb pain and phantom limb site.

Since 1871 Silas Weir Mitchell first coined the term 'phantom limb pain' [21], the pain for the absent limb has been always thought to be 'phantom.' Phantom limb pain is mainly assumed to be related to the disorder of the central or peripheral neurons. Little attention has been paid to the absent limb site where the amputees have designated as the real pain site for hundred of years.

In this investigation, the patient suffered phantom limb pain and could not "move" his phantom limb before the FIR treatment. He had his missing limb more relaxed and controllable after FIR exposed to his phantom limb site. This finding implies that the phantom limb pain reduces as the "controllability" as well as the "relaxation" of the phantom limb increases. Also, not all amputees are able to control the movement of their phantom limbs, but only to "imagine moving" their phantom limbs. This finding may be used to differentiate the success and failure in alleviating the phantom limb using mirror therapy or motor imagery therapy [22]-[26].

The analgesic effect of this report indicates that the absent limb site ("phantom limb") relates to the generation and subsistence of phantom limb pain although the connection between the phantom limb site and the CNS is still unknown. We suggest further investigations into central nervous responses to the stimuli at the phantom limb site to understand the mechanism of phantom limb pain.

V. CONCLUSION

We propose a novel, easy, non-invasive and effective treatment modality for phantom limb pain by applying FIR to the phantom limb pain site rather than to the stump. The results indicate that the FIR therapy can reduce phantom limb pain, and the phantom limb site relates to the generation and subsistence of phantom limb pain although the underlying mechanism remains to be elucidated.

REFERENCES

- [1] Melzack R. Phantom limbs and the concept of a neuromatrix. *Trends Neurosci* 1990;13:pp. 88-92.
- [2] Nikolajsen L, Jensen TS. In: Koltzenburg M, McMahon SB, editors. *Wall and Melzack's Textbook of Pain*. Amsterdam: Elsevier, 2005. pp. 961-71.
- [3] Flor H. Maladaptive plasticity, memory for pain and phantom limb pain: review and suggestions for new therapies. *Expert Rev Neurother* 2008 May; 8(5): pp. 809-18.
- [4] Finnerup NB, Sindrup SH, Jensen TS. Chronic neuropathic pain: mechanisms, drug targets and measurement, *Fundam. Clin. Pharmacol.* 2007;21, pp. 129-136.
- [5] Moulin DE, Clark AJ, Gilron I et al. Pharmacological management of chronic neuropathic pain - consensus statement and guidelines from the Canadian Pain Society. *Pain Res Manag.* 2007 Spring;12(1): pp. 13-21.

- [6] Kao J, Wesolowski J, Lema M. Phantom pain: current insights into its neurophysiology and therapy. *Pain Digest* 1997;7: pp. 333-45.
- [7] Flor H, Elbert T, Knecht S, Wienbruch C, Pantev C, Birbaumer N, Larbig W, Taub E. Phantom-limb pain as a perceptual correlate of cortical reorganization following arm amputation. *Nature* 1995 Jun 8;375(6531): pp. 482-4.
- [8] Grüsser SM, Winter C, Mühlnickel W, Denke C, Karl A, Villringer K, Flor H. The relationship of perceptual phenomena and cortical reorganization in upper extremity amputees. *Neuroscience* 2001;102: pp. 263-72.
- [9] Melzack R. Phantom limbs and the concept of a neuromatrix. *Trends Neurosci* 1990;13: pp. 88-92.
- [10] Merzenich MM, Nelson RJ, Stryker MP, Cynader MS, Schoppmann A, Zook JM. Somatosensory cortical map changes following digital amputation in adult monkeys. *J Comp Neurol* 1984;224: pp. 591-605.
- [11] Pons TP, Garraghty PE, Ommaya AK, Kaas JH, Taub E, Mishkin M. Massive Cortical Reorganization After Sensory Deafferentation in Adult Macaques. *Science* 1991;252(5014): pp. 1857-60.
- [12] Ramachandran VS, Rogers-Ramachandran D, Stewart M. Perceptual correlates of massive cortical reorganization. *Science* 1992 Nov 13;258(5085): pp. 1159-60.
- [13] Katz J. Psychophysiological contributions to phantom limbs. *Can. J. Psychiatry* 1992;37: pp. 282-98.
- [14] Sherman RA, Sherman CJ, Bruno GM. Psychological factors influencing chronic phantom limb pain: an analysis of the literature. *Pain* 1987;28: pp. 285-95.
- [15] Giummarra MJ, Gibson SJ, Georgiou-Karistianis N, Bradshaw JL. Central mechanisms in phantom limb perception: the past, present and future. *Brain Res Rev* 2007 Apr;54(1): pp. 219-32.
- [16] Flor H, Nikolajsen L, Jensen TS. Phantom limb pain: a case of maladaptive CNS plasticity? *Nat Rev Neurosci* 2006; 7: pp. 873-81.
- [17] Mackert B-M, Sappok T, Grusser S, Flor H, Curio G. The eloquence of silent cortex. *NeuroReport* 2003; 14: pp. 409-12.
- [18] Chen R, Cohen LG, Hallett M. Nervous system reorganisation following injury. *Neuroscience* 2002; 111: pp. 761-73.
- [19] Harris JA. Cortical origin of pathological pain. *Lancet* 1999; 354: pp. 1464-6.
- [20] MacIver K, Lloyd DM, Kelly S, Roberts N, Nurmikko T. Phantom limb pain, cortical reorganization and the therapeutic effect of mental imagery. *Brain*. 2008 Aug;131(Pt 8): pp. 2181-91.
- [21] Mitchell SW. Phantom limbs. *Lippincott's Magazine* 1871;8: pp. 563-9.
- [22] Chan BL, Witt R, Charrow AP, Magee A, Howard R, Pasquina PF, et al. Mirror therapy for phantom limb pain. *N Engl J Med* 2007;357: pp. 2206-7.
- [23] Ramachandran VS, Rogers Ramachandran D, Cobb S. Touching the phantom limb. *Nature* 1995;377: pp. 489-90.
- [24] Moseley GL, Gallace A, Spence C. Is mirror therapy all it is cracked up to be? Current evidence and future directions. *Pain* 2008 Aug 15; 138(1): pp. 7-10.
- [25] Brodie EE, Whyte A, Niven CA. Analgesia through the looking-glass? A randomized controlled trial investigating the effect of viewing a 'virtual' limb upon phantom limb pain, sensation and movement. *Eur. J. Pain* 2007;11, pp. 428-436.
- [26] Moseley GL. Graded motor imagery for pathologic pain: a randomized controlled trial. *Neurology*. 2006 Dec 26;67(12): pp. 2129-34.