

Beating-heart Mitral Valve Chordal Replacement

Genevieve Laing and Pierre E. Dupont, *Fellow, IEEE*

Abstract— Replacing open-heart surgical procedures with beating-heart interventions substantially decreases the trauma and risk of a procedure. One of the most challenging procedures to perform on the beating heart is valve repair. To address this need, this paper proposes a tool for replacing mitral valve chordae to correct regurgitation. The chordae is secured to the papillary muscle and leaflet using NiTi tissue anchors that also incorporate an internal adjustment mechanism to enable initial adjustment as well as subsequent readjustment of chordae length. Efficacy of the proposed tool for chordae replacement and reduction of regurgitation was demonstrated in an ex-vivo heart simulator.

I. INTRODUCTION

DUE to the high risks of open-heart surgery, catheter interventions have been replacing cardiac surgical procedures. For example, catheters are guided to the heart to perform angioplasty, ablation, deployment of stents, and insertion of valve replacements [1]. In the latter case, catheters have been used successfully to perform valve replacements on aortic and pulmonary valves, which connect the ventricles to arteries. This is achieved by placing a stent valve at the end of the artery as a replacement to the dysfunctional valve. In valves that connect chambers, such as the mitral valve, however, catheter deployment is not possible since this anchoring approach is not feasible.

Mitral valves can be replaced surgically, however, comparative studies have shown a significant increase in survival rates for patients having valve repair rather than replacement [2] and a lower incidence of valve-related complications [3]. Furthermore, repairs are quite successful, with long-term (i.e. greater than 20 years) re-operation rates of 3-17% [4], freedom from regurgitation at 12 years of 65-80% [5] and a reduction of operative mortality from 5.5% for replacement to 1.5% for repair [6]. Despite this success, valve repair remains a very invasive procedure that requires extended use of cardiopulmonary bypass.

Consequently, there has been substantial interest in developing percutaneous approaches to performing the different components of surgical mitral valve repair. These include suturing together the leaflets to create a double orifice valve (e.g., Abbott Mitraclip) [7], decreasing the size of the valve's annulus by pulling two sections of it together

to bring the leaflets closer together (e.g., Mitralign [8]), plicating excess leaflet tissue to ensure proper sealing of the leaflets [9], and installing artificial chordae (e.g., Neochord [10]).

Recent developments in clinical practice have demonstrated that insertion of instruments through the wall of the beating heart is a safe and effective alternative to both surgery and catheter-based interventions [11],[12]. This approach has the benefit of enabling the significantly better control of the instrument tip for manipulating tissue while also avoiding the need for cardiopulmonary bypass.

The proposed instrument for chordae replacement utilizes this approach by entering the beating heart through the free wall of the left atrium as shown in Fig. 1. Chordal replacement is commonly used to treat mitral valve regurgitation (MVR), defined as blood leaking through the closed valve from the left ventricle to the left atrium. If chordae stretch or rupture, they can no longer restrain the motion of the leaflets and so prevent them from prolapsing into the left atrium.

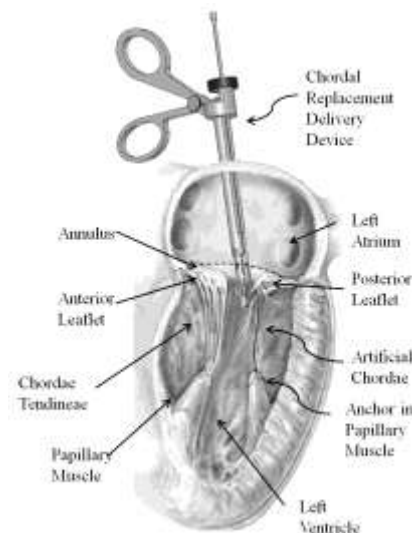


Fig. 1. Cross sectional view of right atrium and ventricular showing mitral and chordal replacement instrument. The artificial chordae replaces the ruptured chordae visible on the posterior leaflet.

Currently, surgeons perform chordal replacement by attaching sutures to the papillary muscle and then to the leaflet. Once the suture is secured with a knot, the artificial chordae cannot be adjusted. If the suture is tied at the incorrect place the chord will need to be cut and the surgeon will begin with a new artificial chord. Mitral valve prolapse, a common cause of MVR, is a progressive disease and therefore even after surgical treatment, regurgitation can become worse. Therefore, an easily re-adjustable artificial

Manuscript received March 25, 2011. This work was supported in part by the National Institutes of Health under grants R01HL073647 and R01HL087797.

G. Laing is with Mechanical Engineering, Boston University, Boston MA 02215 USA (glaing@bu.edu).

P. Dupont is with Cardiovascular Surgery, Children's Hospital Boston, Harvard Medical School, Boston MA 02115 USA (Pierre.Dupont@childrens.harvard.edu)

chordae would be beneficial.

There is only one competitive technology for beating-heart chordal replacement, which accesses the mitral valve through a port in the apex of the heart (Neochord [10]). The device attaches a chordae to the leaflet by stitching a suture through the leaflet. This chordae is then pulled through the heart wall at the apex and tied off on the outside of the heart. Similar to conventional surgery, there is no capability provided to readjust the length of the chordae once it is installed.

The contribution of this paper is to propose a method for beating-heart chordal replacement that also enables subsequent readjustment of chordae length.

The paper is arranged as follows. Section II describes the components of the instrument and the method used to place artificial chordae in the mitral valve. Section III describes the experiments performed to evaluate the device. Conclusions appear in the final section.

II. CHORDAL REPLACEMENT INSTRUMENT AND METHOD

In the proposed procedure, tissue anchors are used to attach the artificial chordae to the papillary muscle and leaflet. These anchors are an adaption of a design previously demonstrated to be effective for securing patches to atrial septal defects [11],[12]. The anchor that is deployed in the leaflet has been modified to enable adjustment of chordal length. The instrument prototype is shown in Fig. 2 and the steps of the procedure are detailed in Fig. 3. First, the delivery device is inserted in the left atrium through the left atrial appendage and the entry hole is secured by purse-string sutures. 3D echocardiography guidance is used for visualization as well as to assess the regurgitation [11],[12].

Once the desired chordae location is determined, the instrument is navigated to the papillary muscle where the first anchor is deployed, as shown in Fig. 3(a). Note that the artificial chordae is secured to the anchor loop. The delivery device is then navigated to the leaflet and the leaflet is grasped between the delivery cannula and the forceps, as shown in Fig. 3(b). Once proper leaflet grasp is confirmed by ultrasound, the second anchor is deployed through the leaflet.

Chordal length can now be adjusted as follows. To shorten the chordae, the delivery cannula is pressed against the leaflet anchor to hold it in place as the suture is pulled from the proximal end of the lumen (Fig. 3(c)). To lengthen the chordae, intracardiac calipers are used to increase the distance between the anchors, forcing the suture to lengthen.

Echocardiography is used to assess mitral valve function and leaflet coaptation. If the chordae is not at the correct length, the adjustment steps can be repeated. Finally, the delivery tubes are replaced with cutting tubes and the excess suture is removed by rotating the two tubes with respect to one another, Fig. 3(d).

Design details of the artificial chordae and the delivery instrument are presented in the subsections below.

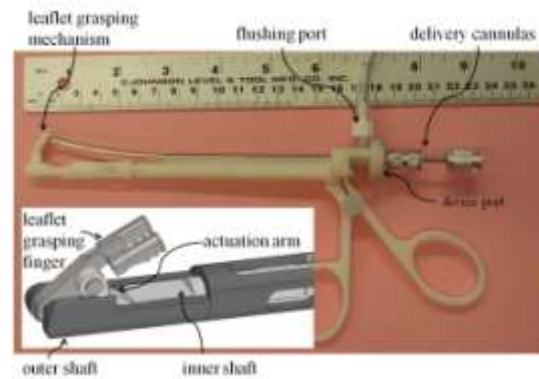


Fig. 2. Chordal replacement instrument prototype.

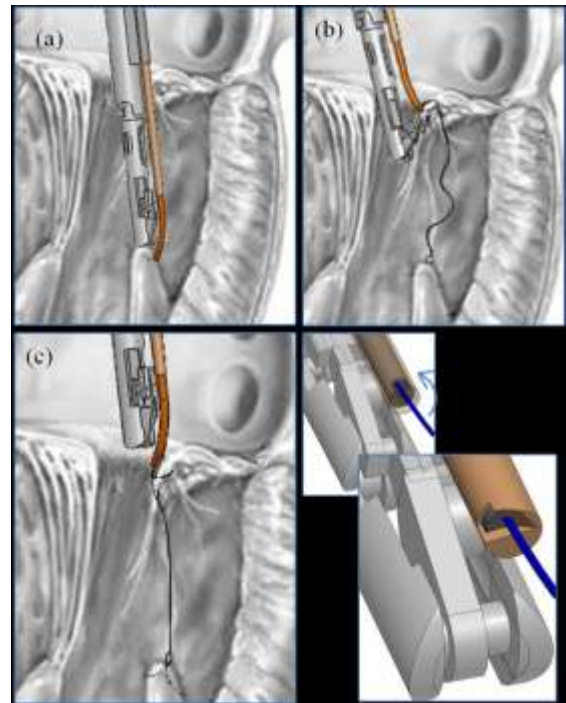


Fig. 3. Artificial chordae delivery procedure steps. (a) Navigate to papillary muscle and place anchor. (b) Navigate to leaflet, grasp leaflet and deploy anchor. (c) Adjust artificial chordae length. (d) Rotate cutting tubes with respect to one another and cut remaining suture.

A. Artificial Chordae Design

As shown in Fig. 4, the artificial chordae consists of two tissue anchors that are tethered together by a Gore-Tex ePTFE suture, a material commonly used to replace chords because of its durability and biocompatibility [13],[14].

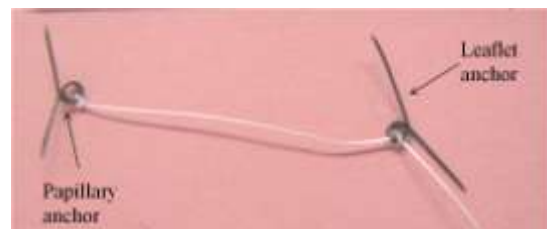

Fig. 4. Chordal replacement instrument prototype.

The method of anchor deployment is shown in Fig. 5. The anchors are made of NiTi wire, which has superelastic properties, and can elastically deform to strains up to 8%. This gives the anchors an ability to bend into an instrument cannula, Fig. 5(b), in order to navigate to the surgical site. When the anchor is pushed through a layer of tissue and released, it springs back into its relaxed shape and is securely attached to the tissue, Fig. 5(d).




Fig. 5. Tissue anchor deployment sequence. Clear cannula is used for visualization. (a) Anchor is attached to hook inside cannula. (b) Anchor is retracted into lumen prior to deployment. (c) Cannula is pressed against tissue and anchor is pushed from cannula so that it pierces through to distal side of tissue. (d) Hook is released from anchor.

The purpose of the papillary anchor is to permanently secure the chordae to the papillary muscle. The suture can be attached to the anchor either by knot or using glue. The anchor must be capable of resisting the tensile forces in the chordae without dislodging from the tissue.

The anchor in the leaflet has two functions. It secures the anchor to the leaflet and also provides the ability to adjust the length of the chordae. The multiple coils of the anchor as shown in Fig. 6 serve as a frictional clamp for the suture that is wrapped around them. The length of the artificial chordae is adjusted by sliding the anchor along the suture. The force required to slide the suture through the clamp must be substantially greater than the maximum tension experienced by the chordae during the cardiac cycle in order to prevent slippage.

During the adjustment process, it is important to grasp both the anchor loop and the suture in order to avoid placing large loads on the leaflet tissue. Shortening of the chordae is accomplished by pushing against the anchor loop with the delivery cannula while pulling on the suture. Lengthening of the chordae is performed by increasing the distance between the anchors using means such as intracardiac calipers [15].




Fig. 6. Tissue anchor with spring adjustment clamp.

B. Delivery Instrument

The delivery instrument is depicted in Figs. 1 and 2. For rapid evaluation of design variations, it was fabricated from

thermoplastic resin using a 3D printer. As shown in Fig. 2, the instrument is comprised of an anchor delivery cannula in combination with a single backward-facing forceps finger, which closes toward the proximal end of the tool. The delivery cannula is comprised of a set of two concentric telescoping pre-curved NiTi tubes, which can manually simulate motions of a concentric tube robot [16]. Rotating and translating the tubes allows the operator to position and orient the cannula tip with respect to the tissue for anchor placement. With the delivery cannula, the surgeon first navigates to the papillary muscle past the distal end of the forceps as shown in Fig. 3a.

To deploy an anchor in the leaflet, the cannula is rotated and retracted so as to form a complete set of forceps with the single instrument finger. Together they are used to trap the leaflet. Once trapped, the instrument finger acts to brace the leaflet as the anchor is forced through the tissue as shown in Fig. 3b. The anchors are guided through the cannula individually by a hook-tipped push rod and released into the tissue at the distal end.

Once the chordae length is adjusted, the push rod is removed and replaced with cutting tubes to remove excess suture. The cutting tubes have sharp edges at the distal end and, when rotated against each other, they cut the suture.

A seal and flush system was integrated into the delivery device to inject heparinized saline into the cannula to prevent emboli formation.

III. EXPERIMENTS

To evaluate the chordal replacement mechanism three tests were performed. First, the strength of the anchors was evaluated by measuring the force required to pull the anchors out of tissue. Anchors were inserted into the tissue as previously described. These experiments were conducted in both papillary and leaflet tissues. Second, the chordal length adjustment mechanism was tested in order to ensure the length would not change based on the tensions in the chordae. Third, the device was tested using an ex-vivo porcine heart simulator to evaluate the artificial chordal replacement method.

A. Pull-out Force Testing

Due to the motion of the leaflets, tension is applied to the chordae during every heartbeat. Forces in the chordae were estimated from mitral valve FEA modeling in [17] to be about 0.3 N. Thus, the force required to pull the anchors out of the papillary muscle and leaflet must exceed this value by a factor of safety. Assuming a safety factor of 3, the pull-out force must exceed 0.9 N.

To evaluate pull-out forces, four anchors were tested in porcine hearts obtained from the supermarket. Each anchor was secured to a suture which was attached to a load cell (Sensotec model 31, 22 N tension/compression). As the anchor was pulled manually from the tissue, the force was recorded. Twenty-one tests were performed on both the papillary and the leaflet.

The average pull-out forces were:

$$F_{\text{papillary}} = 1.31 \pm 0.27 \text{ N}$$

$$F_{\text{leaflet}} = 1.68 \pm 0.51 \text{ N}$$

The papillary muscle is more compliant than the leaflet tissue and therefore less force was required to pull an anchor out of the tissue. These values exceed our desired value of 0.9 N.

B. Friction Clamp Sliding Force Testing

Once the chordae length is adjusted using the friction clamp of the leaflet tissue anchor, the clamping mechanism must be able to resist the chordae forces arising during the cardiac cycle. To evaluate clamp slip force, a linear actuator and load cell (as above) were used to push the cannula against the anchor to generate sliding along the suture.

Two cases were tested in which the suture was looped either once or twice around the coils of the anchor. Fig. 6 depicts the two-loop case. Gore-Tex ePTFE CV-4 suture was used in all of the experiments. These two conditions were tested five times each, on three different anchors. The average sliding forces were:

$$F_{\text{one loop}} = 0.41 \pm 0.14 \text{ N}$$

$$F_{\text{two loops}} = 1.13 \pm 0.16 \text{ N}$$

Using two loops of suture provided sufficient force to exceed our desired value of 0.9 N.

C. Ex-Vivo Chordal Replacement Testing

Ex vivo bench top experiments were also conducted using a heart simulator to reproduce mitral valve leaflet motion. As shown in Fig. 6, the left atrium was removed for complete visualization of the mitral valve. With the heart secured in a water tank by sutures, a microprocessor-controlled pump and solenoid valve system was used to regulate flow in the left ventricle through the aortic valve.

Mitral valve regurgitation was induced in normal valves by cutting one or more primary chordae. An artificial chordae was then implanted using the proposed technique. The results of one such procedure are shown in Fig. 7 where it can be seen that proper sealing of the valve is achieved.

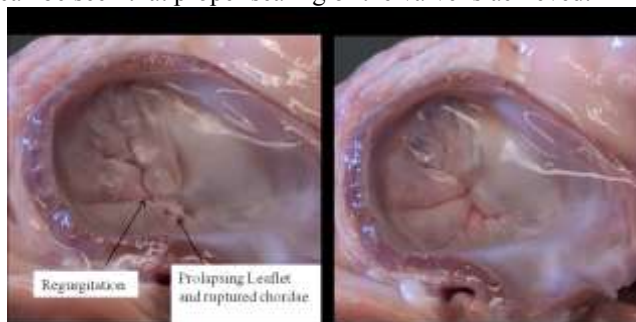


Fig. 5. Porcine mitral valve shown before and after chordal replacement.

IV. CONCLUSION

The proposed technique for beating-heart chordal replacement utilizes the surgically accepted suture in combination with tissue anchors for achieving attachment to the papillary muscle and leaflet tissue. Because the leaflet anchor contains a friction clamp, it is possible not only to

adjust chordal length at the time of installation, but also later, to accommodate changes in the patient's condition.

With the growing acceptance of transmural beating-heart procedures, it may be possible in the future to develop a suite of tools that enable the surgeon to perform all of the necessary components of valve repair. Thus, cardiopulmonary bypass and the trauma associated with open-heart surgery can be avoided while also providing the benefits of valve repair in comparison to valve replacement.

REFERENCES

- [1] D. S. Baim, *Grossman's Cardiac Catheterization, Angiography, and Intervention*. Philadelphia, PA: Lippincott Williams & Wilkins, 2006, pp. 3-12.
- [2] M. Enriquez-Sarano, H. Shaff, T. Orszulak, A. Tajik, K. Bailey and R. Frye, "Valve repair improves the outcome of surgery for mitral regurgitation. A multivariate analysis," *Circulation*, vol. 91(4), pp. 1022-1028, 1995.
- [3] D. Adams, A. Anyanwu, P. Rahmanian and F. Filsoufi, "Current concepts in mitral valve repair for degenerative disease," *Heart Fail Rev.*, vol. 11, pp. 241-257, 2006.
- [4] E. Braunberger, A. Deloche, A. Berrebi et al., "Very long-term results (more than 20 years) of valve repair with carpentier's techniques in nonrheumatic mitral valve insufficiency," *Circulation*, vol. 104(12 Suppl 1), pp. I-8-11.
- [5] T.E. David, J. Ivanov, S. Armstrong, D. Chritie, H. Rakowski, "A comparison of outcomes of mitral valve repair for degenerative disease with posterior, anterior, and bileaflet prolapse," *J Thorac Cardiovasc Surg*, vol. 130(5), pp. 1242-9, 2005.
- [6] <http://www.mitralvalverepair.org> (Mt Sinai Hospital)
- [7] J-B. Masson, J. Webb, "Percutaneous Treatment of Mitral Regurgitation," *Circ Cardiovasc Interv*, vol. 2, pp. 140-146, 2009.
- [8] <http://www.mitralign.com/> (Mitralign)
- [9] N. Vasilyev, F. Freudenthal, D. Perrin, P. Hammer, I. Salgo, P. del Nido, "Repair of Mitral Valve Prolapse in the Beating Heart Using 3D Echo Guidance: A Feasibility Study. International Society for Minimally Invasive Cardiothoracic Surgery," 11th Annual Scientific Meeting, June 11-14, 2008, Boston, MA.
- [10] <http://www.neochord.com/> (Neochord)
- [11] N. Vasilyev, J. Martinez, F. Freudenthal, Y. Suematsu, G. Marx, P. del Nido, "Three-Dimensional Echo and Videocardioscopy-Guided Atrial Septal Defect Closure," *Ann. Thorac. Surg.*, vol. 82(4), pp. 1322-1326, 2006.
- [12] N. V. Vasilyev, I. Melnychenko, K. Kitahori, F. P. Freudenthal, A. Phillips, R. Kozlik-Feldmann, I. S. Salgo, P. J. del Nido, and E. A. Bacha, "Beating-Heart Patch Closure of Muscular Ventricular Septal Defects under Real-Time 3D Echo Guidance: A Pre-Clinical Study," *Journal of Thoracic and Cardiovascular Surgery*, vol. 135(3), pp. 603-609, 2008.
- [13] J. Kobayahi, Y. Sasako, K. Bando, K. Minatoya, K. Niwaya, S. Kitamura, "Ten-Year Experience of Chordal Replacement with Expanded Polytetrafluoroethylene in Mitral Valve Repair," *Circulation*, vol. 102 III, pp. 30-34, 2007.
- [14] L. Salvador, S. Mirone, et. al., "A 20-Year Experience with Mitral Valve Repair with Artificial Chordae in 608 Patients," *The Journal of Thoracic and Cardiovascular Surgery*, pp. 1280-1287, 2008.
- [15] A. Dio, H. Iida, and T. Sunazawa, "Intracardiac Calipers for Artificial Chordae Replacement in Mitral Valve Repair," *Ann. Thorac. Surg.*, vol. 87, pp. 326-329, 2008.
- [16] P. Dupont, J. Lock, B. Itkowitz, and E. Butler, "Design and Control of Concentric Tube Robots," *IEEE Transactions on Robotics*, vol 26(2), pp. 209-225, 2010.
- [17] K. Kunzelman, R. Cochran, C. Chuong, W. Ring, E. Verrier, and R. Eberhart, "Finite Element Analysis of the Mitral Valve," *Heart Valve Disease*, vol. 2, pp.326-340, 1993.