

An automatic detection method for carotid artery calcifications using top-hat filter on dental panoramic radiographs

Tsuyoshi SAWAGASHIRA, Tatsuro HAYASHI, Takeshi HARA, Akitoshi KATSUMATA,

Chisako MURAMATSU, Xiangrong ZHOU, Yukihiro IIDA, Kiyoji KATAGI, and Hiroshi FUJITA

Abstract— The purpose of this study is to develop an automated carotid artery calcification (CAC) detection scheme on dental panoramic radiographs (DPRs). The CAC is one of the indices for predicting the risk of arteriosclerosis. First, regions of interest (ROIs) that include CACs were determined on the basis of inflection points of the mandibular contour. Initial CAC candidates were detected by using a grayscale top-hat filter and simple grayscale thresholding technique. Finally, a rule-based approach and support vector machine to reduce the number of false positive (FP) findings were applied using features such as area, location, and circularity. Thirty-four DPRs were used to evaluate the proposed scheme. The sensitivity for the detection of CACs was 93.6% with 4.4 FPs per image. Experimental results showed that our computer-aided detection scheme may be useful to detect CACs.

I. INTRODUCTION

SURVEYS conducted by the Ministry of Health, Labour, and Welfare in 2009 reveal that heart disease and cerebrovascular disease were 15.8% and 10.7%, respectively, of all mortalities in Japan [1]. These diseases are called "arteriosclerosis diseases." The carotid artery calcifications (CACs) are one of the indices for predicting the risk of arteriosclerosis [2]. Recent findings of dental panoramic radiographs include the clinical information on radiographic signs of CACs [3, 4]. It is likely that some patients with arteriosclerosis disease do not visit medical clinics at their early stages due to its asymptomatic nature. If the risk of arteriosclerotic diseases is explained to patients when dentists detect CACs on panoramic images, these patients can visit medical clinics at their early stages. Such supplemental screening through dentists has a potential to play an important role in preventive medicine. However, general dentists are apt to focus on only dental diseases on panoramic images. For that

Manuscript received June 20, 2011.

T. Sawagashira, T. Hayashi, T. Hara, C. Muramatsu, X. Zhou, and H. Fujita are with the Department of Intelligent Image Information, Division of Regeneration and Advanced Medical Sciences, Graduate School of Medicine, Gifu University, Gifu 501-1194, Japan (e-mail: gashira@fjt.info.gifu-u.ac.jp).

A. Katsumata, and Y. Iida are with the Department of Oral Radiology, Asahi University School of Dentistry, Gifu 501-0296, Japan.

K. Katagi is with the Radiological Technology, Asahi University Hospital, Gifu 501-0296, Japan.

reason, it is likely that radiographic signs of CACs are overlooked. The framework that suggests presence of CAC to dentists may be helpful to solve this problem. The purpose of this study is to develop a computer-aided detection (CADe) scheme for CACs on panoramic images.

II. MATERIALS

Our database consisted of 34 panoramic images including CACs that were obtained at Asahi University Dental Hospital in Japan. The panoramic images were taken with the standard positioning of the head such that the Frankfort horizontal plane was used as a reference line. The automatic mode was used to control the x-ray exposure. It is a standard exposure condition used for a routine dental exam. A panoramic x-ray unit (Veraview Epocs, Morita, Japan) and a computed radiography (CR) system (CR 75.0, Agfa, Germany) were utilized for the acquisition of patients' panoramic radiographs. All calcifications were confirmed by a dental radiologist using the modalities such as CT. This study was approved by the Institutional Review Board of Gifu University and Asahi University.

III. METHODS

The process flow of our scheme is shown with example images in Fig.1. CACs are visualized below and lateral to the mandible on panoramic images. That's why regions of interest (ROI) for CAC detection were determined on the basis of the mandible as the first step [5]. The grayscale values of CACs are higher than those of backgrounds in the ROI, so the morphological grayscale top-hat filter [6] that corrects for trends in background values was used to detect CAC candidates as the second step. This procedure enhances white patterns smaller than the structure element used. The structure element was set as a circle of 15 pixel radius to enhance CAC. However, some parts of cervical vertebrae and hyoid bone that are included in the ROI were also detected as CAC candidates because they had locally high grayscale values. Therefore, cervical vertebrae and hyoid bone were identified and removed from CAC candidates in the third step. False-positive (FP) reduction process was applied based on the features of CAC candidates in the last step.

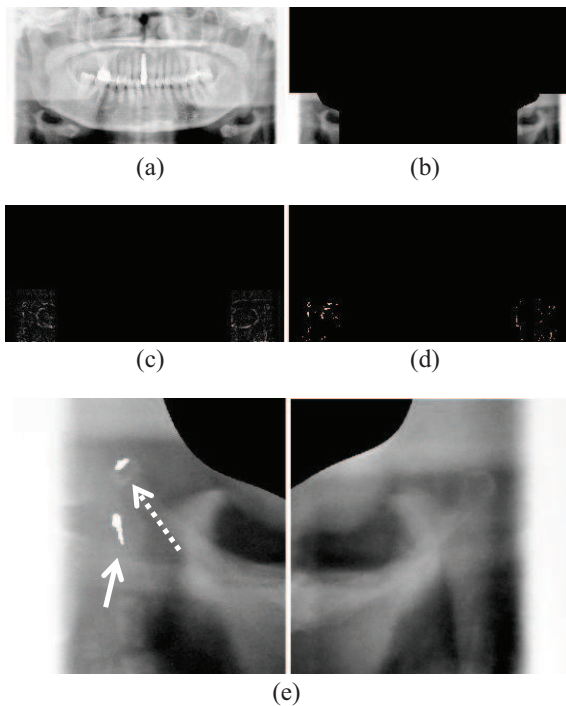


Fig. 1. The process flow of our scheme. (a) original image, (b) ROIs for CAC detection, (c) top-hat transformation result image, (d) initial detection result image, and (e) final result image. The candidate indicated by a solid arrow was correctly detected as CAC in our scheme, but the one indicated by a dotted arrow was incorrectly detected on the hyoid bone.

A. Regions of Interests

The Canny edge detection algorithm was used to detect mandibular contour. After that, the angle of the contour was calculated from the center outward, and the right and left positions that meet the following requirements were assumed to be right and left gonions, respectively as shown in Fig.2 : the first time the angle between a perpendicular line and the tangent to the contour becomes smaller than 15° . If gonions could not be decided, the threshold of the angle was enlarged and the image was scanned again. The ROIs were decided based on the right and left gonions.

B. Determination of Initial Candidates for CACs

A moving-average smoothing with 7×7 pixels was applied to reduce noise of original images. After that, the top-hat filter was used so that the CAC regions were emphasized. The structure element was set as a circle with 1.5-millimeter radius to enhance the CAC. By applying a thresholding technique to the image after top-hat transform, the initial candidates for CAC were

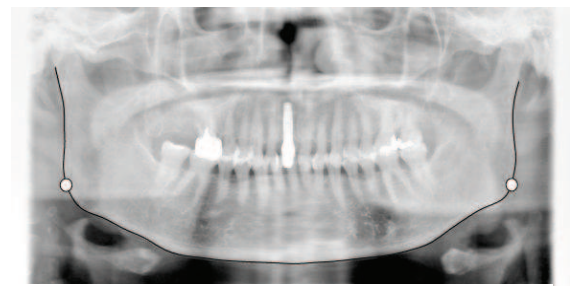


Fig. 2. Determination of gonions.

determined.

C. Elimination of Cervical Vertebrae and Hyoid Bone

The endplates that are parts of cervical vertebrae can appear as horizontal edges. Therefore, a 3×3 sobel filter was applied to the images for emphasizing horizontal edges, and the edges were detected by the thresholding technique. The length of each candidate region was then calculated in the binarized image. Next, the edge with the width from 70 to 150 pixels was assumed to be a short edge, and the edge with 150 pixels or longer was considered to be a long edge. The vertebrae were assumed to be located within a quarter length of the image width from each of the right and left ends of the images. In each of these right and left regions, the number of candidate edges was counted in each column starting from the center of the image. The location where more than 8 short edges or 6 long edges exist was considered to be a boundary of the cervical vertebra, and the region outside of the boundary was excluded from the subsequent process for calcification detection. During this process, the edges corresponding to the hyoid bones were also detected; these locations were also excluded from the search for CACs.

D. Elimination of FP

Using the techniques described in the previous section, most of the CACs was detected accurately. However, the candidates selected initially also included many FPs. For eliminating these, 11 features in each initial candidate for a CAC were determined. These features include the area, average grayscale value, variance of grayscale values, difference of grayscale values between candidate region and surrounding region, height, width, ratio of width and height, circularity, irregularity, and x and y locations. The rule based scheme with 11 features was employed as the first step in the elimination of FPs. In this scheme, we first calculated the maximum and minimum values of all CACs detected in the initial step for identifying the CACs. The total of 22 cutoff thresholds was used for eliminating FPs. For further elimination of FPs, an SVM [7] with 11 features was employed. SVM is a novel generation learning system based on recent

advances in statistical learning machine. In this study, polynomial kernel was used. The soft margin parameter C and the polynomial degree d were 6 and 2, respectively. For training and testing the SVM, the leave-one-out method was employed. The output value of the SVM indicates the likelihood of CACs. By changing the threshold level for the output, we can determine the performance for detection of CACs obtained using our CAD scheme.

IV. RESULTS

Thirty-four panoramic images were used to evaluate the proposed scheme. The sensitivity for the detection of CACs was 93.6%(88/94) with 4.4 FPs per image. Of the 34 cases, the detection of at least one calcification was successful in 33 cases. Examples of results are illustrated in Fig.3. The case 1 in Fig.3 shows that the CAC was overlapped with hyoid bone. Although the CAC indicated by the arrow was detected in our scheme, FP was also detected on the hyoid bone. The case 2 in Fig.3 indicates that the CAC was detected without FP. The case 3 in Fig.3 shows an example in which CAC could not be detected in this experiment. This calcification was quite blur, and the difference of the grayscale value against the backgrounds was small. Therefore, the top-hat filter hardly emphasized this calcification.

Fig. 4 shows the free-response ROC curve for the overall performance of our CAD scheme. This curve was obtained by changing the threshold value for the output value of SVM. The result shows that our CAD scheme achieved the sensitivity of 93.6% (88/94) with 4.4 FP per image.

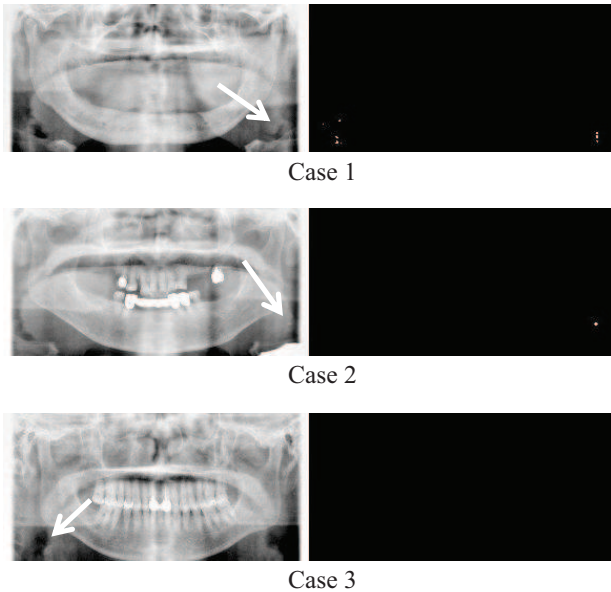


Fig. 3. Examples of results. CACs are indicated by the arrows.

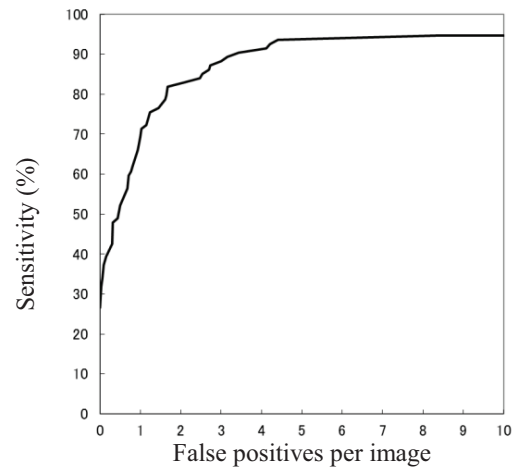


Fig. 4. Free-response ROC curve for the overall performance of our computer-aided detection scheme in the detection of CAC.

V. DISCUSSION

We regulated parameters such as the threshold of the initial candidate detection to improve our previous study [8]. In addition, we used an SVM to eliminate FPs.

A computerized scheme for detecting the CACs on panoramic images was also presented by Izumi et al. [9]. It was based on the grayscale gradient on images. The positions that had the local maximum grayscale values were estimated as CAC regions. However, the direct and quantitative evaluation

and comparison are not possible because databases used are different. Although the sensitivity for detection of CACs obtained using our CAD scheme was reported to be 93.6% in this study, the image database used was collected from only one hospital. In the future, we need to expand our database by collecting images from various scanners from several hospitals and to evaluate our method by using independent databases.

VI. CONCLUSION

We developed a CADe scheme for detection of CACs using morphological grayscale top-hat filter on panoramic images. The experimental results revealed that the sensitivity for the detection of CACs was 93.6%(88/94) with 4.4 FPs per image. Of the 34 cases, the detection of at least one calcification was successful in 33 cases. Therefore, it was suggested that the proposed scheme may have potential to help dentists in the detection of CACs.

ACKNOWLEDGMENT

The authors would like to thank members of the Fujita Laboratory for their valuable discussions, and grateful to Asahi

University Hospital staffs for preparing the panoramic radiographs. This research was supported in part by a Ministry of Education, Culture, Sports, Science and Technology Regional Innovation Cluster Program (City Area Type) in Southern Gifu Area "Development of Advanced Medical Equipment Using Manufacturing Technologies and Information Technologies".

REFERENCES

- [1] Ministry of Health, Labour and Welfare, Vital statistics monthly report in 2009 (In Japanese).
- [2] KR Nandalur, E Baskurt, KD Hagspiel, M Finch, CD Phillips, SR Bollampally, and CM Kramer, Carotid artery calcification on CT may independently predict stroke risk, *Am J Roentgenol*, 186 (2): 545-552, 2006.
- [3] Y Sisman, E Ertas, C Gokce, et al., The prevalence of carotid artery calcification on the panoramic radiographs in Cappadocia region population, *Eur J Dent*, 1 (3): 132-138, 2007.
- [4] M Kumagai, T Yamagishi, N Fukui, et al., Long-term cigarette smoking increases the prevalence of carotid artery calcification seen on panoramic dental radiographs in male patients, *Tohoku J Exp Med*, 212 (1): 21-25, 2007.
- [5] H Fujita, T Hara, A Katsumata, et al., Computer-aided detection system and schemes using panoramic radiographs, Patent pending in Japan, 2011-060256 (applied on 18 Mar, 2011).
- [6] H. Kobatake, *Morphology*, Corona sha Co, Tokyo, 1996 (In Japanese).
- [7] Cristianini N and Taylor JS, *An introduction to support vector machines and other kernel-based learning methods*, New York: Cambridge University Press, 2000.
- [8] T Hayashi, T Sawagashira, T Hara, et al., A method to detect calcified region using grayscale top-hat filter on dental panoramic radiographs, *IEICE Technical Report*, MI2009-138, 337-400, 2010 (In Japanese).
- [9] Y. Izumi, K. Shinjo, M. Muneyasu, et al., An automatic detection method for carotid artery calcification in dental panoramic radiographs for screening of atherosclerosis – A new method considering intensity gradients -, *IEICE Technical Report*, MI2010-58, 43-48, 2010 (In Japanese).