

# Localized BIA identifies structural and pathophysiological changes in soft tissue after post-traumatic injuries in soccer players

L. Nescolarde, J. Yanguas, H. Lukaski, G. Rodas, J. Rosell-Ferrer, *Senior Member, IEEE*

**Abstract**— Localized bioimpedance (BIA) was measured with a single frequency phase-sensitive analyzer at 50 kHz in three post-traumatic types of injuries on four professional soccer players: (1) myositis ossificans, (2) intramuscular seroma and (3) trochanteric (hip) bursitis. Normal reference value (no injury) was obtained from the contra lateral not injured limb at a mirror-like location of the injury. The relative variations resistance (R) and reactance (Xc) at the time of injury was confronted with the not injured values. Relative variations between acute measurements and post medication ones on intramuscular seroma and bursitis have been computed. In intramuscular seroma and trochanteric bursitis we have obtained a percent of change between injury data and after medical intervention. On myositis ossificans, localized BIA showed a 7-8 % decrease in Xc whereas the percent of change of R was negligible (1 %). These percent of changes are in concordance with histological evidence. In the case of a presence of seroma or the lower thigh and trochanteric bursitis, the soft tissue cavity accumulates fluid. Post-injury localized BIA, relative with respect to non-injured side, confirmed sizeable soft tissue destruction evidenced by 50 % decrease of Xc and 24-31 % decrease of R due to interstitial fluid accumulation. Once the seroma and the blood in the bursitis was removed the localized the immediate post-injury BIA parameters increased as follows: a) intramuscular seroma + 10 % on R and + 74 % of Xc; b) trochanteric bursitis + 20 % of R and +24 % of Xc. Localized BIA other than classifying soft tissue injuries, can be useful to understand the pathophysiology and structural impairments of other kind of injuries and to understand their behavior.

L. Nescolarde is with the Electronic Engineering Department, Universitat Politècnica de Catalunya, Jordi Girona 31, 08034-Barcelona, Spain (e-mail: lexa.nescolarde@upc.edu).

J. Yanguas is with the Medical Department of Futbol Club Barcelona, Aristides Maillol s/n, 08028-Barcelona, Spain and with the Department of Surgery, Universitat Autònoma de Barcelona, Campus UAB, 08913-Bellaterra, Barcelona, Spain (e-mail: xavier.yanguas@fcbarcelona.cat).

H. Lukaski is with the Department of Kinesiology and Public Health Education, Hyslop Sports Center, University of North Dakota, Grand Forks ND 58202, USA (e-mail: henry.lukaski@email.und.edu).

G. Rodas is with the Medical Department of Futbol Club Barcelona, Aristides Maillol s/n, 08028-Barcelona, Spain (e-mail: gil.rodas@fcbarcelona.cat).

J. Rosell-Ferrer is with the Electronic Engineering Department, Universitat Politècnica de Catalunya, Jordi Girona 1-3, 08034-Barcelona, Spain (e-mail: javier.rosell@upc.edu).

## I. INTRODUCTION

Bioimpedance analysis (BIA) is a safe, practical and non invasive method to measure the electrical responses to the introduction of a low-level alternating current into a living organism. A 50 kHz, phase-sensitive bioimpedance analyzer yields passive bioelectrical measurements of impedance (Z) and its components including resistance (R), which is the opposition to the flow of an alternating current through intra- and extra-cellular ionic solutions, and reactance (Xc), which indicates the capacitive component of tissue interfaces and cell membranes concentration. The parameter Xc is associated with the cells density and integrity of soft tissue structures and R with hydration state of soft tissue [1].

Localized BIA has been used to study muscle injuries in professional soccer players [2, 3] showing a pattern of reduction of complex bioimpedance parameters (R, Xc and PA) directly related to the severity of the injuries. Also, a similar method based on measuring local electrical impedance of muscle groups, has been used for the evaluation of neuromuscular damage [4].

Soccer is a high risk activity for muscle injury because it includes repetitive efforts of sprinting, kicking and jumping [5] and it is a “contact” sport [6].

The aim of this study is to analyze the changes of localized BIA measurements over recurrent types of injuries that can occur in soccer: post-traumatic myositis ossificans, post-traumatic intramuscular seroma and post-traumatic trochanteric (hip) bursitis.

## II. MATERIAL AND METHODS

### A. Sample

Four different male players belonging to the under-18 team of Futbol Club Barcelona (FCB) participated as volunteers in the study. Guardians of each player signed an informed consent and the local medical committee of FCB approved the study.

Two players were affected of a post-traumatic myositis ossificans, one player was affected of a post-traumatic intramuscular seroma and the last one, a goalkeeper, was affected of a post-traumatic trochanteric bursitis.

Measurements were made in the Medical Department of FCB when the players called for medical care after they

were injured.

*B. Electrode placement*

Four adhesive contact electrodes Ag/AgCl (COVIDIEN Ref. 31050522, COVIDIEN llc, Mansfield, USA) were placed over the area of the injured muscle. The pair of sensing electrode was placed, after supine position, 5cm from either side from the center-line of the injury and the current source couple was positioned close to sensors. These electrodes have an encased conductive pre-gelled spot and the adhesive encircling part is not conductive.

*C. Bioimpedance Analyzer*

A BIA single frequency tetra-polar BIA (BIA 101 Anniversary AKERN/RJL Systems) was performed using an alternating sinusoidal electric constant current of 400  $\mu$ A at an operating single frequency of 50 kHz. The device was verified daily for its calibration using the standard control circuit supplied by the manufacturer having a known complex impedance circuit (Resistance = 380  $\Omega$ ; Reactance = 47  $\Omega$ ). The accuracy of the device was 1% for resistance (R) and 1% for reactance (Xc).

*D. Data Analysis*

According to our previous findings [2, 3] we observed as a normal reference, the contra lateral non-injured side. We calculated the percent of change in R and Xc at the time of injury. In cases of medical treatment (intramuscular seroma and trochanteric bursitis), we obtained in addition the percent of change between acute injury data and after medication.

*E. Diagnostic method*

All injuries were diagnosed by ultrasound (LOGIQ e, GE Healthcare; Milwaukee, WI; USA).

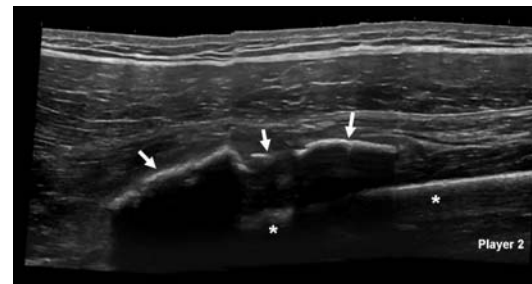
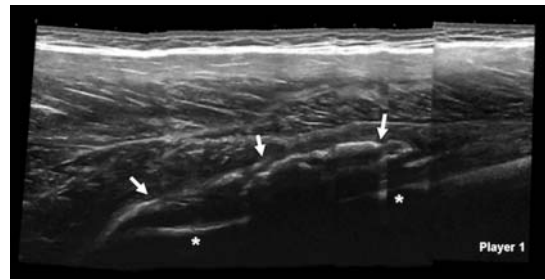


Figure 1: US longitudinal image of the anterior thigh. The myositis ossificans is view as an irregular hyperechoic line (arrows) upper the femur (asterisks).

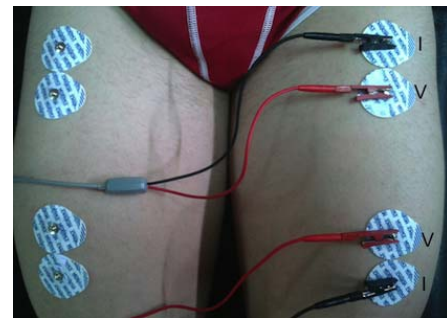


Figure 2: Electrode placement to assess myositis ossificans.

III. CASE REPORTS AND RESULTS

***Type 1: Post-traumatic myositis ossificans***

Two soccer players (17 years, 1.70 m, 64.5 kg and 18 years, 1.73 m, 69.6 kg respectively) called for medical attention because of continuing discomfort due to a direct trauma occurred at the anterior thigh 6 weeks before. Both players kept playing normally during this time. The ultrasound (US) scan showed a myositis ossificans in each player (Figure 1). Figure 2 shows the electrode placement method and Table 1 reports the localized BIA measurements.

TABLE 1  
LOCALIZED BIA IN CASE OF MIOSITIS OSSIFICANS

	No injured thigh		Injured thigh (6 weeks after contusion)		% of change	
	R ( $\Omega$ )	Xc ( $\Omega$ )	R ( $\Omega$ )	Xc ( $\Omega$ )	R	Xc
<b>Player 1</b>	37.7	14.8	37.2	13.6	↓1.3	↓8.11
<b>Player 2</b>	38.9	16.7	38.5	15.5	↓1.3	↓7.19

***Type 2: Post-traumatic intramuscular seroma***

A soccer player (17 years, 1.75 m, 72.2 kg) asked for attention for discomfort and swelling of the lower thigh 10 days after a direct trauma of the anterior thigh. He could play normally during this time. The US scan showed a vast intramuscular seroma (Figure 3) and 80 milliliters was removed by ultrasound-guided needle aspiration. Figure 4 shows the electrode placement, Figure 5 identifies the

medical intervention and removal of fluid and Table 2 presents the results obtained after aspiration of the seroma.

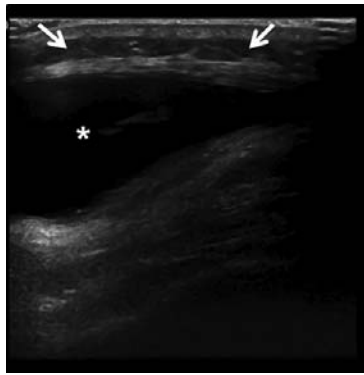

Figure 3: US transversal image of the lower thigh showing an important liquid, anechoic, intramuscular collection (asterisk) just under the subcutaneous tissue (arrows).

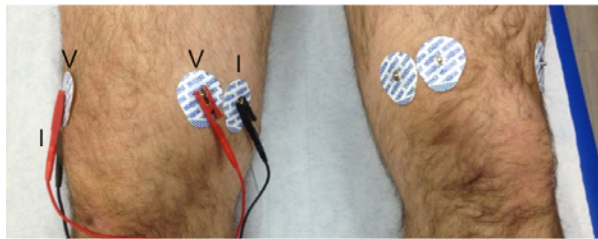


Figure 4: Electrode placement to assess intramuscular seroma.

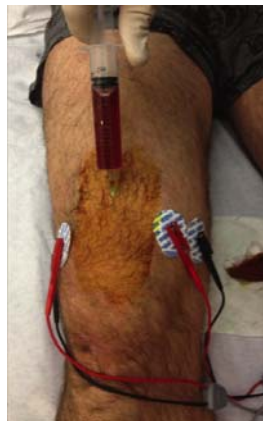

Figure 5: Medical intervention in post-traumatic intramuscular seroma in which 80 cm<sup>3</sup> of fluid (seroma) was removed by needle aspiration.

**Type 3: Post-traumatic trochanteric bursitis**

A goalkeeper (17 years, 1.83 m, 76.3 kg) called for attention for an important swelling in his lateral hip due to repeated trauma. Ultrasound confirmed the presence of a trochanteric bursitis (Figure 6) and 30 milliliters of blood were removed by ultrasound-guided needle aspiration. Figure 7 shows the electrode placement, Figure 8 identifies the medical intervention and Table 3 presents the results obtained after aspiration of bursitis' content.

TABLE 2  
LOCALIZED BIA IN CASE OF INTRAMUSCULAR SEROMA

Time of measure	BIA parameters		
	R ( $\Omega$ )	Xc ( $\Omega$ )	
No injured thigh (1)	43.6	13.6	
Injured thigh (2)	10 days after trauma	30.2	6.8
% of change (2 vs. 1)		↓30.7	↓50.0
Post-aspiration (3)	10 days after trauma	33.2	11.8
% of change (3 vs. 2)		↑10.0	↑73.5
% of change (3 vs. 1)		↓23.9	↓13.0

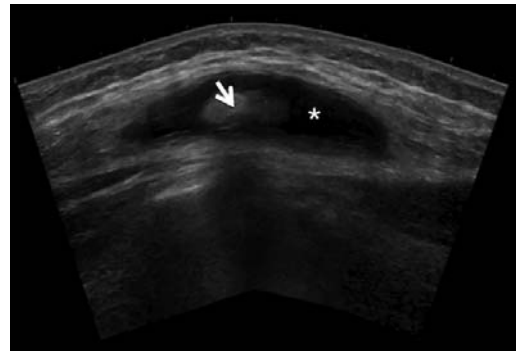


Figure 6: US longitudinal image of the lateral hip showing a trochanteric bursitis. A residue of subcutaneous tissue (arrow) is involved in a liquid cavity (asterisk).

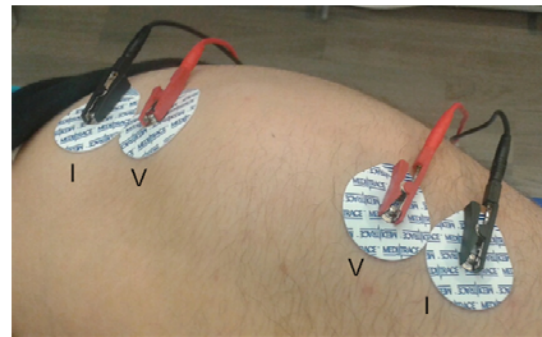


Figure 7: Electrode placement to assess trochanteric bursitis.

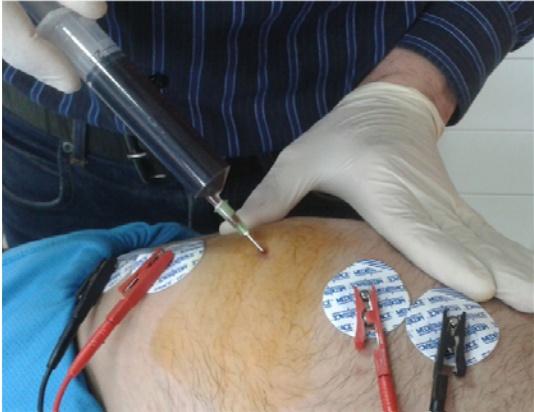

Figure 8: Medical intervention in post-traumatic trochanteric bursitis from which 30 cm<sup>3</sup> of fluid (blood) was removed by needle aspiration.

TABLE 3  
LOCALIZED BIA IN CASE OF TROCHANTERIC BURSTITIS

	Time of measure	BIA parameters	
		R ( $\Omega$ )	Xc ( $\Omega$ )
No injured hip (1)		39.5	8.6
Injured hip (2)	1 week after the last contusion after	30.1	4.2
% of change (2 vs. 1)		↓23.8	↓51.2
Post-aspiration (3)	1 week after the last contusion after	36.1	5.2
% of change (3 vs.2)		↑20.0	↑23.8
% of change (3 vs.1)		↓8.6	↓40.0

#### IV. DISCUSSION

Three specific different types of post-traumatic injuries relatively common in soccer have depicted.

Type 1: The myositis ossificans is a heterotopic calcification into the muscle than can appear after an important direct contusion usually in anterior or lateral thigh; its aetiology is still unknown [7]. After some weeks this injury can be diagnosed by image tests. If localized BIA is applied, some interesting changes can be seen. In the two cases of myositis ossificans described, Xc decreased (7-8 %). However the percent of change obtained in R was negligible since it is within the range of measurement error of the BIA analyzer (1 %). These percent of changes are in concordance to the histology: fibroblasts, osteoblasts, multinucleated giant cells, degenerated muscle cells and osteoid [8].

Type 2 and 3: The seroma of the lower thigh (type 2) due to a knee contusion and the trochanteric bursitis (type 3) from repeated trauma in a goalkeeper, behave as liquid-filled cavities. Localized BIA after injury, compared to non-injury values (measured on contra lateral side), support significant muscle tissue destruction with 50% decrease of reactance

(Xc) and a 24-31% decrease of resistance (R) due to fluid accumulation. Once the seroma and the blood in the bursitis have been removed, the localized BIA parameters increased: +10 % of R and +73.5 % of Xc in type 2 intervention, and +3, 20% of R and +23.8 % of Xc in type 3 intervention. However respect to the non-injury contra lateral values the parameters decreased: -23.9 % of Xc and -13.0 % of R in type 2, and -8.6 % of R and -40.0 % of Xc in type 3 intervention.

#### V. CONCLUSIONS

Although the sample size is limited, findings are consistent. Localized BIA could be used to assess muscle injuries until recovery and also to understand their behaviour.

#### VI. ACKNOWLEDGMENTS

Authors wish to thank the FCB football players who consented to participate in this study.

#### REFERENCES

- [1] Lukaski HC, Piccoli A, "Bioelectrical impedance vector analysis for assessment of hydration in physiological states and clinical conditions," In: Preedy V (ed) Handbook of Anthropometry Springer: London UK, pp. 287-315, 2012.
- [2] Nescolarde L, Yanguas J, Medina D, Rodas G, Rosell-Ferrer J, "Assessment and follow-up of muscle injuries in athletes by bioimpedance: preliminary results," Conf Proc IEEE Eng Med Biol Soc., pp. 1137-40, 2011.
- [3] Nescolarde L, Yanguas J, Lukaski H, Alomar X, Rosell-Ferrer J, Rodas G, "Localized bioimpedance to assess muscle injury," *Physiol. Meas.*, vol. 34, pp. 237-245, 2013.
- [4] Rutkove SB, "Electrical Impedance Myography: Background, Current State, and Future Directions," *Muscle Nerve*, vol. 40, pp. 936-946, 2009.
- [5] Cross TM, Gibbs N, Houang MT, Cameron M, "Acute quadriceps muscle strains: magnetic resonance imaging features and prognosis," *Am. J. Sports Med.*, vol. 32, pp. 710-9, 2004.
- [6] Arnason A, Sigurdsson SB, Gudmundsson A, Holmes I, Engebretsen L, Bahr R, "Risk factors for injuries in football," *Am. J. Sports Med.*, vol. 32, pp. S5-S16, 2004.
- [7] Beiner JM, Jokl P, "Muscle contusion injury and myositis ossificans traumatica," *Clin Orthop Relat Res.*, vol. 403 Suppl., pp. S110-9, 2002.
- [8] Klapsinou E, Despoina P, Dimitra D, "Cytologic findings and potential pitfalls in proliferative myositis and myositis ossificans diagnosed by fine needle aspiration cytology: report of four cases and review of the literature," *Diagn. Cytopathol.*, vol. 40, pp. 239-44, 2012.